



E-ISSN: 2278-4136
P-ISSN: 2349-8234
JPP 2018; 7(3): 1081-1083
Received: 23-03-2018
Accepted: 27-04-2018

VS Modh

P.G. Scholars, Dept. of
Veterinary Surgery & Radiology,
Dr. V.M. Jhala Clinical complex,
College of Veterinary Science &
A.H. SDAU, Deesa, Gujarat,
India

PB Patel

Professor, Dept. of Veterinary
Surgery & Radiology, Dr. V.M.
Jhala Clinical complex, College
of Veterinary Science & A.H.
SDAU, Deesa, Gujarat, India

AM Patel

Asst. Professor, Dept. of
Veterinary Surgery & Radiology,
Dr. V.M. Jhala Clinical complex,
College of Veterinary Science &
A.H. SDAU, Deesa, Gujarat,
India

PT Sutaria

Asst. Professor, Dept. of
Veterinary Surgery & Radiology,
Dr. V.M. Jhala Clinical complex,
College of Veterinary Science &
A.H. SDAU, Deesa, Gujarat,
India

JB Patel

Asst. Professor, Dept. of
Veterinary Surgery & Radiology,
Dr. V.M. Jhala Clinical complex,
College of Veterinary Science &
A.H. SDAU, Deesa, Gujarat,
India

AM Patel

P.G. Scholars, Dept. of
Veterinary Surgery & Radiology,
Dr. V.M. Jhala Clinical complex,
College of Veterinary Science &
A.H. SDAU, Deesa, Gujarat,
India

NS Chaudhari

P.G. Scholars, Dept. of
Veterinary Surgery & Radiology,
Dr. V.M. Jhala Clinical complex,
College of Veterinary Science &
A.H. SDAU, Deesa, Gujarat,
India

Correspondence**VS Modh**

P.G. Scholars, Dept. of
Veterinary Surgery & Radiology,
Dr. V.M. Jhala Clinical complex,
College of Veterinary Science &
A.H. SDAU, Deesa, Gujarat,
India

Surgical management of congenital apocrine carcinoma of tail in Mehsana buffalo calf: A rare case

VS Modh, PB Patel, AM Patel, PT Sutaria, JB Patel, AM Patel and NS Chaudhari

Abstract

A 6 hours old male Mehsana buffalo calf presented with a history of congenital large swelling at base of tail extended ventrally to the anus. Upon clinical examination found a coconut size swelling anchoring anus to the tail. The positive contrast radiograph with barium enema revealed clear rectal tract. Under epidural anesthesia, whole mass was resected out with tail amputation. In histopathological examination, neoplasm was diagnosed as apocrine carcinoma. The surgical wound healed on 12th post-operative day and animal having a normal feeding and defecation. This case describes surgical management and histopathology of rare congenital apocrine carcinoma in buffalo calf.

Keywords: apocrine carcinoma, buffalo calf, congenital swelling, mehsana, positive contrast radiograph, tail

Introduction

Apocrine carcinoma is a sweat gland epithelium originated malignant type tumor (Moulton, 1978) [12] which is congenitally rare in calves and has been reported (Misdorp, 2002 and Phaneendra *et al.*, 2016) [7]. Apocrine sweat gland tumors are common in dogs than bovines (Hazirolu *et al.*, 2014) [5]. Present case describes surgical management of congenital apocrine carcinoma of tail in Mehsana buffalo calf.

Case history and clinical observations

A 6 hours old male Mehasana buffalo calf weighted about 26 k.g. was presented at Dept. of Veterinary Surgery & Radiology, SDAU, Deesa with a history of congenital swelling at tail extended ventrally to the anus. Muconium yet not passed by animal. Palpation of swelling revealed hard mass. Observed a coconut size hard swelling anchoring anus to tail (Fig 1). By inserting fingers into anus, muconium was passed by animal as the tumour mass suppressed the rectum (Fig 2). Positive contrast radiography performed using barium enema revealed clear rectal tract (Fig 3). Ultrasonography examination revealed a hard mass inside the swelling. All the physiological and hematological parameters were within normal range.

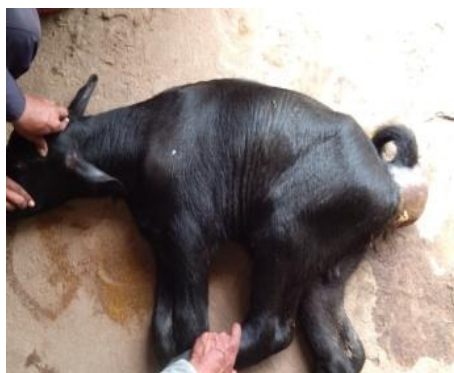


Fig 1

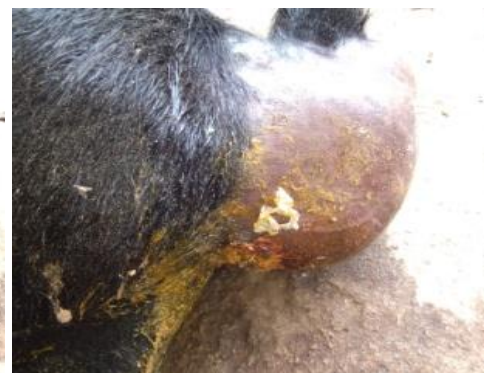

Fig 2

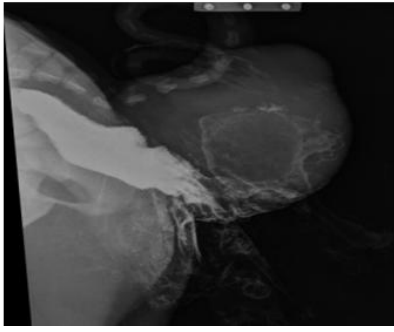

Fig 3

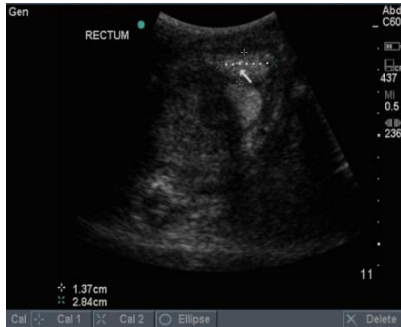

Fig 4

Surgical management

Under epidural anaesthesia, whole mass was resected out with tail amputation by applying elliptical incision over swelling. Hemorrhage was controlled by digital pressure and ligation of major tail's blood vessels. Surgical wound was sutured first in subcutaneously by using chromic catgut # 1 in simple continuous running suture pattern and then skin by using braided silk # 2 in horizontal mattress followed by simple continuous suture pattern. A half cut 10 ml syringe was fixed to anus for easy passing of stools (Fig 5). Post operatively case was managed with antibiotic (Gentamicin @ 4.4 mg/kg), analgesic (Meloxicam @ 0.2 mg/kg) and antihistaminic (Pheniramine maleate @ 50 mg T.D.) for 5 days and daily antiseptic dressing.

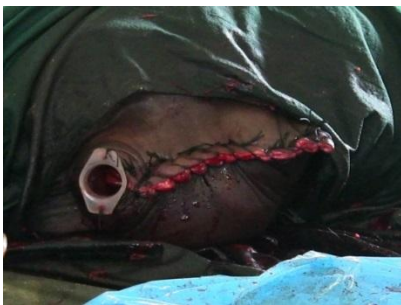

Fig 5

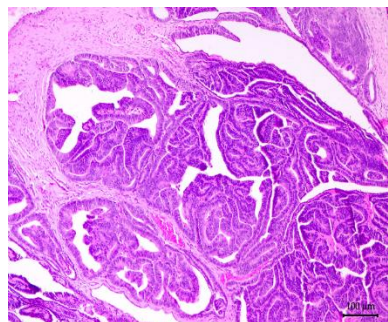


Fig 6

Histopathology

Microscopically, neoplasm was composed of single layer columnar epithelium arranged in tubules with multiple arborizing papillary projections into lumen and separated by delicate fibrovascular stroma. There were mild anisocytosis and anisokaryosis. Mitotic figures average 2 per 10 high power fields (Fig 6). On basis of histopathological examination, neoplasm was diagnosed as apocrine carcinoma.

Result and Discussions

Surgical wound healed on 12th post-operative day with passing stool normally (Fig 7) and up to 6 months telephonic follow up, no any reoccurrence of growth was observed by owner on animal body. Such surgery helped to save animal and a lactation of dam.

Congenital tumors especially carcinomas are rare in domestic animals and difficult to differentiate from other malformation and tumor present at birth (Misdorp, 1965 and Misdorp, 2002) [6, 7]. Frequently occurred congenital tumors in bovine are nephroblastoma, rhabdomyosarcoma, tubular adenomas of testes, benign melanoma, multiple lipomas, fibrosarcoma, mesotheloma of peritoneum (Grant, 1958, Misdorp, 1965, Misdorp, 2002) [3, 6, 7]. Congenital apocrine sweat gland tumor are rare in animals but acquired form were found in adult cattle (Piercy *et al.*, 1994, Gulbahar *et al.*, 2002, Tessele *et al.*, 2015) [11, 4], in a bull (Garma-Avina and Valli, 1981) [2], in horse at prepuce (Anderson *et al.*, 1990) [1], in mouflon (Morandi *et al.*, 2005) [9], in rabbit at subcutis of the caudal abdomen (Miwa *et al.*, 2006) [8].

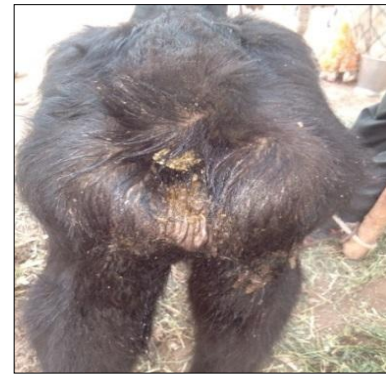

Fig 7

References

1. Anderson WI, Scott DW, Cramer FM. Two rare cutaneous neoplasms in horses: apocrine gland adenocarcinoma and carcinosarcoma. *The Cornell Veterinarian* 1990; 80(4):339-45.
2. Garma-Avina A, Valli VE. Mixed sweat gland tumor in a bull (a case report). *Vet. Med. Small Anim. Clin.* 1981; 76:557-559.
3. Grant CA. Congenital tumours of calves. *Transboundary and emerging diseases.* 1958; 5(3):231-244.
4. Gulbahar MY, Alkan I, Aslan L, Golen I. Mixed Apocrine Sweat Gland Tumor of the Tail in a Cow. *Veterinary Pathology.* 2002; 39:281-285.
5. Haziroglu R, Haligur M, Keles H. Histopathological and immunohistochemical studies of apocrine sweat gland adenocarcinomas in cats. *Veterinary and comparative oncology.* 2014; 12(1):85-90.
6. Misdorp W. Tumors in new born animals. *Path. Vet.* 1965; 2:328-343.

7. Misdorp W. Congenital tumours and tumour-like lesions in domestic animals. 1. Cattle A review. *Veterinary Quarterly*. 2002; 24(1):1-11.
8. Miwa Y, Mochiduki M, Nakayama H, Shubuya N, Ogawa H, Sasaki N. Apocrine adenocarcinoma of possible sweat gland origin in a male rabbit. *Journal of Small Animal Practice*. 2006; 47:541- 544.
9. Morandi F, Benazzi C, Simoni P. Adenocarcinoma of apocrine sweat glands in a mouflon (*Ovis musimon*). *Journal of Veterinary Diagnostic Investigation*. 2005; 17:389-392.
10. Phaneendra MSSV, Veena P, Saibaba M, Prasad WLNV. Apocrine Gland Adenocarcinoma of tail in a Buffalo Calf (*Bubalus bubalis*)- A case report. *Journal of Livestock Science*. 2016; 7:165-167.
11. Piercy DWT, Cranwell MP, Collins AJ. Mixed apocrine (sweat gland) adenocarcinoma in the tail of a cow. *Veterinary Record*. 1994; 134:473-474.
12. Moulton JE. Tumors in domestic animals. Edn 2, University of California Press, Ltd., London, 1978, 59.
13. Tessele B, Rissi DR, Langohr IM, Vielmo A, Barros CSL. Mixed apocrine adenocarcinoma of the tail in a cow. *Brazilian journal of Veterinary Pathology*. 2015; 8(2):72-75.