



E-ISSN: 2278-4136
P-ISSN: 2349-8234
JPP 2018; 7(3): 1072-1077
Received: 16-03-2018
Accepted: 19-04-2018

Binita Angom

a) Department of Pharmacology,
College of Veterinary Sciences &
Animal Husbandry, Agartala,
Tripura, India

b) Department of Pharmacology
& Toxicology, C.V.Sc & A.H.,
Aizawl, India

Pritam Mohan

Department of Pharmacology &
Toxicology, C.V.Sc & A.H.,
Assam, India

C Lalmuanthanga

Department of Pharmacology &
Toxicology, C.V.Sc & A.H.,
Aizawl, India

Prabhakar Maurya

Central Insecticides Board &
Registration Committee,
Faridabad, India

Khangembam Victoria Chanu

ICAR-Directorate of Coldwater
Fisheries Research, India

Correspondence**Binita Angom**

a) Department of Pharmacology,
College of Veterinary Sciences &
Animal Husbandry, Agartala,
Tripura, India

b) Department of Pharmacology
& Toxicology, C.V.Sc & A.H.,
Aizawl, India

Hepatoprotective activity of aqueous extract of *Dendrocnide sinuata*, (Blume) Chew

**Binita Angom, Pritam Mohan, C Lalmuanthanga, Prabhakar Maurya
and Khangembam Victoria Chanu**

Abstract

Background and Objective: *Dendrocnide sinuata* root decoction is used by various ethnic communities of North East India for curing jaundice but there is no scientific documentation. The study aimed to explore hepatoprotective activity of *D. sinuata* roots against carbon tetrachloride induced hepatotoxicity in Wistar rats.

Materials and Methods: Aqueous extract of *D.sinuata* root bark (AEDS) by cold extraction. Phytochemical screening of AEDS was done. Five groups of 6 rats each were used. Group 1: Healthy control group, Group II: Hepatotoxicity induced with carbon tetrachloride but untreated, Group III: Administered carbon tetrachloride (CCl₄) and silymarin @ 100 mg.kg⁻¹, Group IV: Administered carbon tetrachloride (CCl₄) and AEDS @ 30 mg.kg⁻¹, Group V: Administered carbon tetrachloride (CCl₄) and AEDS @ 100 mg.kg⁻¹. Hepatoprotective activity of ADS was evaluated by analyzing liver function marker enzymes in the serum. Histopathological studies of liver were carried out.

Result: Dose dependent hepatoprotective effect of AEDS against carbon tetrachloride induced hepatotoxicity was observed. There was significant hepatic protection indicated by the serum enzymes levels which was comparable to that of silymarin treated group which is also supported by histological findings.

Conclusion: Oral administration of AEDS @ 100 mg.kg⁻¹ body weight significantly ameliorates CCl₄ hepatotoxicity in rats.

Keywords: hepatoprotective, *Dendrocnide sinuata*, carbon tetrachloride, liver function test

Introduction

Liver is a vital organ of vertebrates with multiple functions required for normal functioning of body systems. Its variable roles include detoxification, biosynthesis, metabolism and many others adding up to 500 different functions (Zakim, David *et al.*, 2002) ^[1]. Since liver plays a central role in drug metabolism and clearing of chemicals from the body, it becomes prone to chemical induced injury. Chemical agents used in different areas as well as many drugs are reported to induce liver injury. As many as more than 900 drugs either overdose or within therapeutic limit have been implicated in liver toxicity (Friedman, Scott E *et al.*, 2003) ^[2]. Liver damage is indicated by increase in its biochemical markers, alanine transferase (ALT), alkaline phosphatase (ALP) and bilirubin beyond its normal upper limit (Mumoli N *et al.*, 2006; Benichou C., 1990) ^[3, 4]. Considering the importance of the organ, many advances have made in treatment and management of liver diseases. However, modern therapeutics available has either little to offer against hepatotoxicity or is not free from adverse side effects. Therefore, search of anti-hepatotoxic drugs are turning towards plant based folk remedies. Various researches on traditional medicinal plants for hepatoprotective activity are being carried out against carbon tetrachloride induced hepatotoxicity. The present study also aims at exploration of the hepatoprotective activity of *Dendrocnide sinuata*. It is a medicinal plant randomly used by various ethnic communities of north east India for curing disease condition like jaundice (Lalfakzuala R *et al.*, 2006) ^[5]. Usage of the root decoction against jaundice in folklore medicine indicates that the plant must be having some hepatoprotective activity. Though the medicinal property of the plant is known, there is no scientific documentation as per our knowledge. This has prompted us to analyze the phytochemicals in the root extract of *D. sinuata* and explore its hepatoprotective activity against chemical induced liver injury.

Materials and Methods***Dendrocnide sinuata* roots**

D. sinuata along with roots were collected from the campus of College of Veterinary Science and Animal Husbandry, Aizawl (Mizoram). The Regional Office, Botanical Survey of India (BSI), Shillong authenticated the plant vide letter No. BSI/ERC/ Plant Ident./2011/86 dated

27/05/2011. The roots were washed gently under tap water till it is free from soil and wiped with blotting paper, and weighed. The roots were air dried in shed for a period of one week. Dried roots were ground to powder and stored in an air tight container at -4°C till further use.

Experimental animals

Adult healthy Wistar rats (100-120 grams body weight) of either sex were procured from M/S Chakraborty Enterprises, Ltd. Kolkata. All the animals were housed in polypropylene cages in small groups of 6 rats per cage. Animals had free access to standard balanced ration and clean drinking water *ad libitum*, and were maintained in standard laboratory conditions (12:12 hour light/dark cycle at ambient temperature ranging between 12-25°C). Experimental protocols were approved by Institutional Animal Ethics Committee (IAEC), vide letter number CVSC/CAU/IAEC/11-12.

Preparation of extract

Dry powdered root of *D. sinuata* was subjected to cold aqueous extraction as per the method used by Manjunatha and coworkers (Manjunatha B K *et al.*, 2005) [6] with slight modification. 125 grams of powdered roots of were soaked in 1 (one) litre of double distilled water for 4 days and was filtered with muslin cloth followed by Whatman filter paper number 1. Further the extract was lyophilized (Operon Freeze Dryer) and stored at -40°C. Hereafter, the aqueous extract of *D. sinuata* root will be referred as AEDS.

Phytochemical study

AEDS was tested for its phytochemical constituents like (test for tannins, phlobatannins, saponins, flavonoids, steroids terpenoids by Salkowski test, cardiac glycosides by Keller – Killani test, anthraquinones, reducing sugars by Fehling's test) following protocol of Edeoga and coworkers (Edeoga H O *et al.*, 2005) [7].

Induction of hepatotoxicity and treatment

A total of 30 (thirty) Wistar rats were taken for the study. After one week of adaptation at the local environment, the rats were divided into 5 (five) groups of six rats (n=6) each. Group I rats were maintained as normal healthy group which received standard diet and *ad libitum* water only. Group II, III, IV and V rats were administered carbon tetrachloride (CCl₄) in liquid paraffin (50% v/v @ 2ml / kg) twice a week for 28 days by subcutaneous injection following the protocols of Jayasekhar and coworkers (Jayasekar P *et al.*, 1997) [8] to induce hepatic damage. Group II served as induced but untreated control. Group III rats received silymarin, a known hepatoprotective drug (Micro Labs Limited) @ 100 mg.kg⁻¹ orally daily for 28 days simultaneously with carbon tetrachloride and kept as standard treatment control. In addition to carbon tetrachloride injection, Group IV and V were simultaneously given AEDS @ 30 mg.kg⁻¹ and 100 mg.kg⁻¹ body weights respectively orally daily for 28 days.

Blood collection and biochemical tests

Blood samples were collected separately in sterilized micro centrifuge tubes by puncturing inner retro-orbital plexus of the eye on 0, 7th, 14th, 21st and 28th day. Serum separated from blood samples were assayed spectrophotometrically (UV-Vis Spectrophotometer, Chemito) for biochemical parameters viz., Alanine Transaminase (ALT), Aspartate

Transaminase (AST), Alkaline Phosphatase (ALP), bilirubin, total protein, cholesterol and triglycerides following the instructions given in the kit (Crest Biosystems).

Histopathological examination

Rats were sacrificed on 28th day of study using chloroform and liver tissues were collected in 10% formalin. The tissues were further processed and stained with for Haematoxylin and Eosin for histopathological study as described by Luna (Luna L G., 1968) [9].

Statistical Analysis

Observed values were expressed as mean ± SEM and were subjected to statistical analysis by employing ONEWAY ANOVA and POSTHOC-DUNCAN ALPHA (P≤0.05) test for accurate comparison and meaningful interpretation between control and treatment groups using the software SYSTAT-SPSS.

Results

Phytochemical tests

AEDS was qualitatively analyzed for the presence of different phytochemical constituents. The extracts were found to contain terpenoids, flavonoids, saponins, tannins and cardiac glycosides as shown in Table 1.

Table 1: Qualitative phytochemical analysis of aqueous extract *Dendrocnide sinuata* roots

Sl. No.	Phytochemical/Compound	Result
1.	Alkaloid	–
2.	Anthraquinone	–
3.	Cardiac glycoside	++
4.	Flavonoid	+++
5.	Reducing sugar	–
6.	Saponin	++
7.	Steroid	–
8.	Tannin	++
9.	Terpenoid	+++
10.	Phlobatannin	–

Acute toxicity test of the extract

AEDS @ 2000 mg.kg⁻¹ P.O (post oral), caused mortality in one mouse out of three mice. The same experiment was repeated at the same dose rate of the extract. No mortality could be observed during the repeated experiment. Based on the observations, LD₅₀ dose was calculated as per OECD-425 guidelines and found to be 2500 mg.kg⁻¹ P.O.

Tests for marker enzymes and other biochemical parameters

There was no significant difference in the total protein level in all the groups. Significant increase in the enzyme level (ALT, AST and ALP) were observed in Group II as compared to Group I however silymarin treated (Group III) and AEDS treated (Group IV and V) showed enzyme level lower than Group II (Fig1). Mean values of total protein, AST, ALT and ALP of each group are presented in Table2. Significant increase in total bilirubin and cholesterol was observed in hepatotoxic induced but untreated group (Group II) as compared to control group. Difference in the direct bilirubin and triglyceride among the groups are not significant (Fig2). Mean values of the biochemical parameters of each group are listed in Table3.

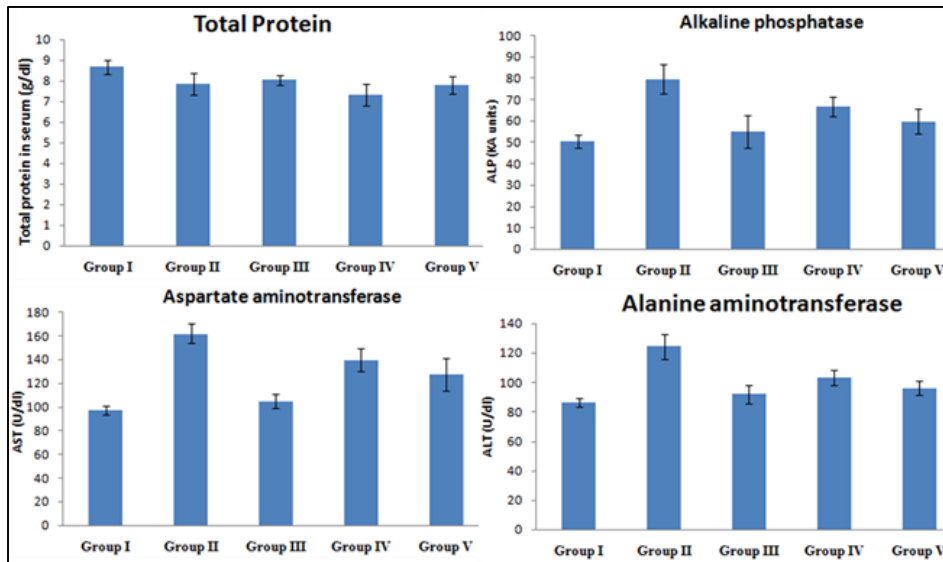


Fig 1: Level of total protein and enzymes (ALP AST and ALT and) in healthy (Group I), hepatotoxic induced (Group II) and treated (Group III, IV, V) Wistar rats

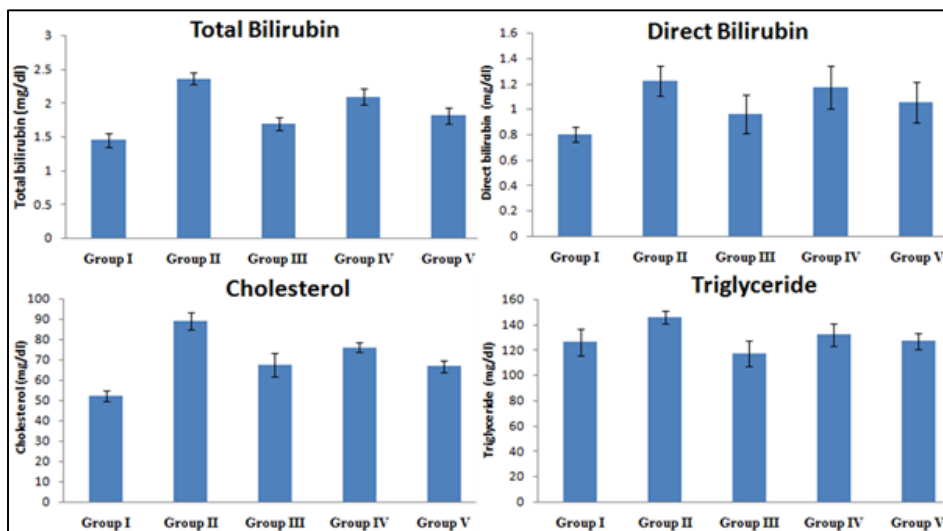


Fig 2: Level of total bilirubin, direct bilirubin, cholesterol and triglyceride in in healthy (Group I), hepatotoxic induced (Group II) and treated (Group III, IV, V) Wistar rats

Table 2. Effect of aqueous extracts of *D. sinuata* on total protein, aminotrasferases and alkaline phosphatases

Group	Treatment (mg/kg body weight, PO)	Total Protein (g/dl)	Aspartate Aminotransferase (U/dl)	Alanine Aminotransferase (U/dl)	Alkaline Phosphatase (KA Units)
I	Control	8.67±0.33	97.33±3.49 ^d	86.333±3.07 ^d	50.26±2.96 ^c
II	CCl ₄ 2ml/kg SC	7.83±0.53	162.00±8.03 ^a	124.33±8.30 ^a	79.58±6.74 ^a
III	CCl ₄ +Silymarin (100)	8.03±0.25	104.80±5.71 ^{cd}	92.00±6.16 ^{cd}	54.99±7.87 ^{bc}
IV	CCl ₄ +AEDS (30)	7.32±0.52	139.66±9.33 ^{ab}	103.00±5.28 ^{bc}	66.73±4.71 ^{ab}
V	CCl ₄ +AEDS (100)	7.78±0.41	127.67±13.92 ^{bc}	96.00±4.92 ^{cd}	59.72±5.76 ^{bc}
F-Value		1.43 ^{NS}	5.72 ^{**}	4.58 ^{**}	3.315 [*]

Values are mean ± SEM, n=6 in each groups. Means bearing different superscript in a column differed significantly (P<0.05) NS - Non Significant. AEDS – Aqueous extract of *D. Sinuata* roots.

Table 3: Effect of aqueous extract of *D.sinuata* on bilirubin, cholesterol and triglyceride

Group	Treatment (mg/kg body weight, PO)	Total Bilirubin (mg/dl)	Direct Bilirubin (mg/dl)	Cholesterol (mg/dl)	Triglyceride (mg/dl)
I	Control	1.45±0.10 ^d	0.80±0.06	52.24±2.78 ^c	126.01±10.56
II	CCl ₄ 2ml/kg SC	2.36±0.09 ^a	1.22±0.12	88.94±4.14 ^a	145.50±5.08
III	CCl ₄ +Silymarin (100)	1.69±0.09 ^{cd}	0.96±0.15	67.36±5.79 ^{bc}	116.84±10.66
IV	CCl ₄ +AEDS (30)	2.09±0.12 ^{ab}	1.17±0.17	76.02±2.32 ^{ab}	132.13±8.82
V	CCl ₄ +AEDS (100)	1.81±0.12 ^{bc}	1.05±0.16	66.66±3.06 ^{bc}	126.94±6.47
F-Value		7.732 ^{**}	1.145 ^{NS}	4.45 ^{**}	1.44 ^{NS}

Values are mean ± SEM, n=6 in each groups. Means bearing different superscript in a column differed significantly (P<0.05) NS - Non Significant. AEDS – Aqueous extract of *D. Sinuata* roots.

Histopathological examination

Histopathological studies revealed an extensive hepatic damage in case of CCl₄ treated group. De-arrangement of hepatic cells, fatty infiltration, vacuolation and hemorrhage of the hepatocytes were observed. Centrilobular necrosis and steatosis were also observed in CCl₄ treated group. Group III and Group V treated with silymarin and AEDS (100 mg.kg⁻¹ P.O) respectively showed a protective effect as decreased extent of centrilobular necrosis and steatosis could be observed (Fig. 3).

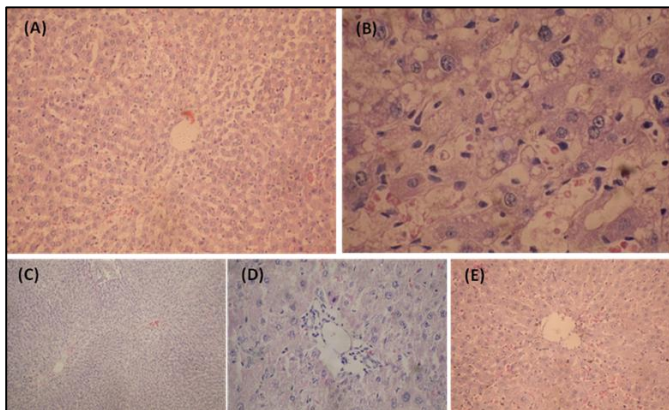


Fig 3: Haematoxylin and Eosin staining of liver section of all the five groups (A) Normal control liver at 100X (B) Group II (CCl₄ treated) showing severe fatty change and cellular swelling in the hepatic parenchyma at 400X; (C) Group III (CCl₄+Silymarin @ 100 mg.kg⁻¹) showing centrilobular and perilobular fatty change, 100X; (D) Group IV (CCl₄+ AEDS @ 30 mg/kg) showing mild cellular swelling in hepatocytes, 200X; (E) Group V CCl₄+AEDS @ 100 mg/kg) showing complete regeneration of hepatic lobule with mild sinusoidal congestion at 200X.

Discussion

Medicinal properties of *Dendrocnide sinuata* are known to ethnic tribal communities of north eastern states of India and they have been using the plant as medicine in traditional healing of fever, malaria, dysentery, urinary disorder, irregular menstruation, blind abscesses and hypersensitivity¹⁰. Roots and leaves in the form of poultice to heal boils, carbuncles, wounds, burns and rashes. Roots are effective against both Gram positive and Gram negative bacterial due to the presence of 2a,3,21,24,28-pentahydroxy-olean-12-enes (Paul T.K. *et al.*, 2012) [11]. Root decoction is used to cure jaundice. Since roots of this plant are used for curing jaundice, it was hypothesized that the roots must be having some hepatoprotective property. As liver plays an important role in detoxification and excretion of many endogenous and exogenous compounds, any injury or impairment of its function may lead to several implications on one's health. Since conventional drugs used in the treatment of liver diseases are often inadequate, management of liver diseases is still a challenge to modern medicine. It is therefore necessary to search for alternative or traditional drugs which is effective in treatment of liver diseases and poses minimum or no cytotoxicity to the patient.

In our experiment, carbon tetrachloride was used to induce hepatotoxicity in rats. Carbon tetrachloride (CCl₄) is a routinely used hepatotoxin in experimental studies of liver diseases. CCl₄ mediates changes in liver function that ultimately leads to destruction of hepatocellular membrane. Inside the body, CCl₄ is activated by cytochrome P-450 to form various free radicals like trichloromethyl, CCl₃ and trichloromethylperoxy, CCl₃OO etc (Seakins A *et al.*, 1963)

[12]. CCl₃ diffuses through cell membrane causing lipid peroxidation of membranes. Damages in plasma membrane lead to cell swelling, influx of Ca²⁺ and mitochondrial damage ultimately causing cell death. Ribosomal disaggregation results in decrease protein synthesis and hence no formation of apolipoproteins resulting in the accumulation of lipids and fatty change. CCl₃OO also affect the permeability of mitochondrial endoplasmic reticulum, and plasma membranes by attacking on unsaturated fatty acids of phospholipids present in the cell membrane. Consequently, a chain of lipid peroxidation occurs followed by loss of cellular calcium sequestration and homeostasis and finally cell death. Among the degradation products of fatty acids, 4-hydroxynonenal binds easily to functional groups of proteins and inhibits important enzyme activities¹³. The resultant changes in enzyme levels are the marker liver injury which can be measured to determine the extent and type of hepatocellular damage.

In the present study, total protein, Aspartate Aminotransferase (AST), Alanine Aminotransferase (ALT) and serum Alkaline Phosphatase (ALP) level in the serum was measured spectrophotometrically. Serum total protein, though not significant, was found to be lower in rats treated with CCl₄ only as compared to healthy group. Liver is the major source of serum proteins, most importantly, albumin. In the present experiment, the study period was only 28 days, so, total protein or albumin level may not be a reliable indicator of acute liver diseases since the half life of albumin in serum is as long as 20 days (Thapa BR *et al.*, 2007) [14]. Enzymes (ALT, AST and ALP) level in group II was found to be significantly increased as compared to healthy control group. Aminotransferases (ALT and AST) are liver specific enzymes that catalyze the inter-conversion of amino acids and α -keto acids by the transfer of amino groups. These enzymes are very sensitive and their levels in serum increases when the integrity of liver cells are affected by toxic compounds (Subramoniam A *et al.*, 1999) [15]. Alkaline phosphatase was also found to be increased in group II which is an indicative of hepatobiliary diseases (Burtes C A *et al.*, 1986) [16]. When compared to the control group (Group I) and Group II which received only CCl₄, silymarin treated group has higher enzyme level than group I but less than the untreated group (Group II). Group V which received CCl₄ and AEDS @ 100 mg.kg⁻¹ showed enzyme levels lower than group II and similar to that of silymarin treated group. Enzyme levels in group IV which received CCl₄ and AEDS @ 30 mg.kg⁻¹ body weight lies between that of group II and group V. It indicates that AEDS is hepatoprotective in a dose dependent manner. Decreased levels of transaminases in group III, IV and V indicate healing of hepatic parenchyma and the regeneration of hepatocytes from the damage caused by hepatotoxin. Reduced alkaline phosphatase level in AEDS treated group indicates that the increased biosynthesis of the enzyme under biliary pressure had been controlled.

CCl₄ toxicity in group II led to increase in total bilirubin and cholesterol significantly. There was also elevation of direct (conjugated bilirubin) and triglyceride in the serum. Increase in bilirubin might have resulted from decreased hepatic clearance due to liver diseases (Thapa BR *et al.*, 2007) [14]. Higher levels of serum conjugated (direct) bilirubin are seen in hepatocellular damage, toxic or ischemic liver injury (Gowda S *et al.*, 2009) [17]. Silymarin and AEDS (@100 mg.kg⁻¹ b.wt.) treated group showed significant reduction in total bilirubin level as compared to group II. Reduction in direct bilirubin was also observed in the treated group though

not significant. Changes in the level of triglyceride and cholesterol might be due to the influence of hepatic injury on lipid metabolism. Hyperlipidemia with increased in plasma triglyceride and cholesterol level has been reported in animals with cholestasis (Meyer D J *et al.*, 1985; Bauer J E *et al.*, 1989) [18, 19]. The increased in cholesterol can be explained in part by the inability of the liver to remove and catabolize cholesterol due to the hepatic damage and cholestasis as revealed by rise in direct bilirubin level. AEDS administered @ 100 mg/kg body weight could significantly reduce the cholesterol level which was found to be comparable to the standard hepatoprotective drug silymarin.

Damage to hepatocytes in CCl₄ induced toxicity may be due to the production of highly reactive free radicals like trichloromethyl free radicals (CCl₃[•]) and trichloromethyl peroxy free radicals (CCl₃OO[•]) (Fang *et al.*, 2008; Weber *et al.*, 2003; De Groot *et al.*, 1988; Masuda and Nakamura, 1990) [20, 21, 22, 23]. And protection conferred by AEDS may be from the antioxidant effects of the phytochemicals. Phytoconstituents like the flavonoids (Baek N L *et al.*, 1996) [24] tri-terpenoids (Xiong X *et al.*, 2003) [25] and saponins (Tran Q I *et al.*, 2003) [26] present in AEDS are known to possess antioxidant activity as well as hepatoprotective activity. Flavonoids possess wide spectrum of biological action including hypoazotemic, hypotensive, hypoglycemic, oestrogenous, spasmolytic, chloragogue, anti-inflammatory, anti-lipemic and anti-oxidants activities (Oladele S B *et al.*, 2003) [27].

The hepatoprotective activity of AEDS is further supported by the histopathological findings in the liver sections. In the CCl₄ induced hepatic damage, the liver section revealed widespread derangement of hepatic cells which are characterized by fatty infiltration, vacuolation of the hepatocytes as the fats leaked out from the cells leaving a vacuole. Some amount of hemorrhage was also observed in the liver of group II rats. In silymarin and AEDS treated groups, regeneration of hepatic lobule with mild sinusoidal congestion was observed. The present findings provide scientific evidence to the ethno medicinal use of this plant by the tribal people of north-east India in treating jaundice. The potential usefulness of the extract in clinical conditions associated with liver damage is still to be demonstrated. Future investigations are needed for the isolation of the active principle responsible for hepatoprotective activity.

Acknowledgements

The authors are grateful to Central Agricultural University, Imphal and Dean, College of Veterinary Science and Animal Husbandry, Aizawl for funding and providing necessary facilities for the research work.

Conflict of Interest

We declare no conflict of interest.

References

- Zakim David, Boyer Thomas D. *Hepatology: A Textbook of Liver Disease*. Edn 4, 2002.
- Friedman, Scott E, Grendell James H, McQuaid, Kenneth R. *Current Diagnosis & Treatment in Gastroenterology*. Edn 2, Lang Medical Books/McGraw-Hill, New York; 2003, 664.
- Mumoli N, Cei M, Cosimi A. Drug-related Hepatotoxicity. *N. Engl. J. Med.* 2006; 354(7):731-9.
- Benichou C. Criteria of Drug-Induced Liver Disorders. Report of an International Consensus Meeting. *J. Hepatol.* 1990; 11(2):272-6.
- Lalfakzuala R, Lalramnghinglova H, Kayang H. Ethnobotanical Usages of Plants in Western Mizoram. *Indian J Tradit Know.* 2007; 6(3):486-493.
- Manjunatha BK, Vidya SM, Rashmi KV, Mankani KL, Shilpa HJ, Jagadeesh S. Evaluation of Wound Healing Potency of *Vernonia arborea* Hk. *Indian J. Pharmacol.* 2005; 37:223-226.
- Edeoga HO, Okwu DE, Mbaebie BO. Phytochemical constituents of some Nigerian medicinal plants. *Afri. J. Biotechnol.* 2005; 4(7):685-688.
- Jayasekar P, Mohanan PV, Rathinam K. Hepatoprotective activity of ethyl acetate extract of *Acacia catechu*. *Ind. J. Pharmacol.* 1997; 29(6):426-428.
- Luna LG. *Manual of Histological Staining Methods of the Armed Forces Institute of Pathology*, Edn 3, Mc Graw Hill Book Co., New York, 1968.
- Tanti B, Buragohain AK, Gurung L, Kakati D, Das AK, Borah SP. Assessment of Antimicrobial and Antioxidant activities of *Dendrocnide sinuata* (Blume) Chew leaves- A medicinal plant used by ethnic communities of North East India. *Indian Journal of Natural Products and Resources.* 2010; 1(1):17-21.
- Paul TK, Kumar A. *Dendrocnide sinuata* (Blume) Chew [*Urticaceae*] – A plant that can be grown to repulse the Wild Elephants. *Envis Newsletter.* 2012; 14(2):5.
- Seakins A, Robinson DS. The effect of the administration of carbon tetrachloride on the formation of plasma lipoproteins in rats. *Biochem J.* 1963; 86:401.
- Weber LW, Boll M, Stampfl A. Hepatotoxicity and mechanism of action of haloalkanes: Carbon tetrachloride as a toxicological model. *Crit Rev Toxicol.* 2003; 33:105.
- Thapa BR, Anuj W. Liver Function Tests and their Interpretation. *Indian J Pediatr.* 2007; 74:663-671.
- Subramoniam A, Pushpangadan P. Development of phytomedicines for liver diseases. *Indian J Pharmacol.* 1999; 31:166.
- Burtes CA, Ashwood ER. *Textbook of Clinical Chemistry*. WB Saunders Co, Philadelphia; 1986, p56.
- Gowda S, Desai PB, Hull VV, Math AAK, Vernekar SN, Kulkarni SS. A Review on Laboratory Liver Function Tests. *The Pan African Medical Journal.* 2009; 3:17.
- Meyer DJ, Chiapella AM, Cholestasis. *Vet Clin. N. Am. Small. Anim. Pract.* 1985; 15:215.
- Bauer JE, Meyer DJ, Goring RL, Beauchamp CH, Jones J. Lipoprotein cholesterol distribution in experimental induced Canine Cholestasis. In: *"Nutrition of the Dog and Cat"*. I. H. Burger and J. P. W. Rivers, Eds.; Cambridge University Press, New York. 1989; 343-352.
- Baek NL, Kim YS, Kyung JS, Park KH. Isolation of anti-hepatotoxic agents from the roots of *Astragalus membranaceus*. *Korean J Pharmacog.* 1996; 27:111.
- Xiong X, Chen W, Cui J, Yi S, Zhang Z, Li K. Effects of Ursolic acid on Liver Protection and Bile Secretion. *Zhong Yao Cai.* 2003; 26(8):578-581.
- Tran QI, Adnyana IK, Tezuka Y, Nagaoka T, Tran QK, Kadota S. Triterpene saponins from Vietnamese ginseng (*Panax vietnamensis*) and their hepatocyte protective activity. *J Nat Prod.* 2001; 64:456.
- Oladele SB, Ayo JO, Audaudi AO. Medicinal and physiological properties of flavonoids, coumarin derivatives and anthraquinones of plant origin. *West Afri J of Pharm and Drug Res.* 1995; 11:134.
- Fang HL, Lai JT, Lin WC. Inhibitory effect of olive oil on fibrosis induced by carbon tetrachloride in rat liver. *Clin Nutr.* 2008; 27:900-7.

25. Weber LW, Boll M, Stampfl A. Hepatotoxicity and mechanism of action of haloalkanes: carbon tetrachlorides as a toxicological model. *Crit Rev Toxicol.* 2003; 33:105-36.
26. De Groot H, Littauer A, Hugo-Wisseemann D, Wisseemann P, Noll T. Lipid peroxidation and cell viability in isolated hepatocytes in a redesigned oxystat system: Evaluation of the hypothesis that lipid peroxidation, preferentially induced at low oxygen partial pressure is decisive for CCl_4 liver cell injury. *Arch. Biochem. Biophys.* 1988; 264:591-599.
27. Masuda Y, Nakamura Y. Effects of oxygen deficiency and calcium omission on carbon tetrachloride hepatotoxicity in isolated perfused livers from phenobarbital-pretreated rats. *Biochem. Pharmacol.* 1990; 40:1865-1876.