



E-ISSN: 2278-4136

P-ISSN: 2349-8234

JPP 2019; 8(3): 3014-3018

Received: 10-03-2019

Accepted: 12-04-2019

Vivekanandhan R

Ph.D. Scholar, Department of Veterinary Public Health, College of Veterinary and Animal Sciences, Mannuthy, Kerala, India

Shanmuganath C

Veterinary Assistant Surgeon, Kadalaiyur Veterinary Dispensary, Kovilpatti, Tamilnadu, India

B Sunil

Professor, Department of Veterinary Public Health, College of Veterinary and Animal Sciences, Mannuthy, Kerala, India

Anukampa Kadwalia

Ph.D. Scholar, Division of Veterinary Public Health, ICAR-IVRI, Izatnagar, Bareilly, Uttar Pradesh, India

Bhoomika

Ph.D. Scholar, Division of Veterinary Public Health, ICAR-IVRI, Izatnagar, Bareilly, Uttar Pradesh, India

Muralikrishna P

Research Assistant, Meat Technology Unit, College of Veterinary and Animal Sciences, Mannuthy, Kerala, India

Murugavelu M

MVSc Scholar, Department of Veterinary Public Health, College of Veterinary and Animal Sciences, Mannuthy, Kerala, India

Correspondence**Vivekanandhan R**

Ph.D. Scholar, Department of Veterinary Public Health, College of Veterinary and Animal Sciences, Mannuthy, Kerala, India

Dirofilariasis: An emerging zoonoses

Vivekanandhan R, Shanmuganath C, B Sunil, Anukampa Kadwalia, Bhoomika, Muralikrishna P and Murugavelu M

Abstract

Dirofilariasis is one of the emerging zoonotic parasitic diseases accidentally affecting the humans (dead-end host), caused by filarial nematodes of genus *Dirofilaria*, subgenus *Nochtiella*. It infects various domestic and wild animals naturally and canines are the principal reservoir hosts. They are known to cause accidental infections in humans. *D. repens* is the prevalent species identified in India. Mosquitoes of the genera *Aedes*, *Culex*, *Anopheles*, *Mansonia* and *Armigeres* species are reported to be associated in its transmission while a blood meal, mosquitoes deposit hemolymph on the wound, which conveys infectious "larvae 3" stage that enters the host's skin on their own. The clinical signs include coughing, exercise intolerance, unthriftiness, dyspnea, cyanosis, hemoptysis, syncope, epistaxis, and ascites. Preventing infection in dogs can be done by daily administration of diethylcarbamazine during and after heartworm season. The introduction of the macrolide agents such as ivermectin, milbemycin, moxidectin and selamectin has provided the veterinary profession with effective heartworm preventatives in a variety of formulations. Dirofilariasis can be prevented by avoiding mosquito bites by the use of insect repellent when exposed to mosquitoes and by sleeping under an insecticide-treated bed net.

Keywords: *Dirofilaria*, emerging, mosquitoes, canines and humans

Introduction

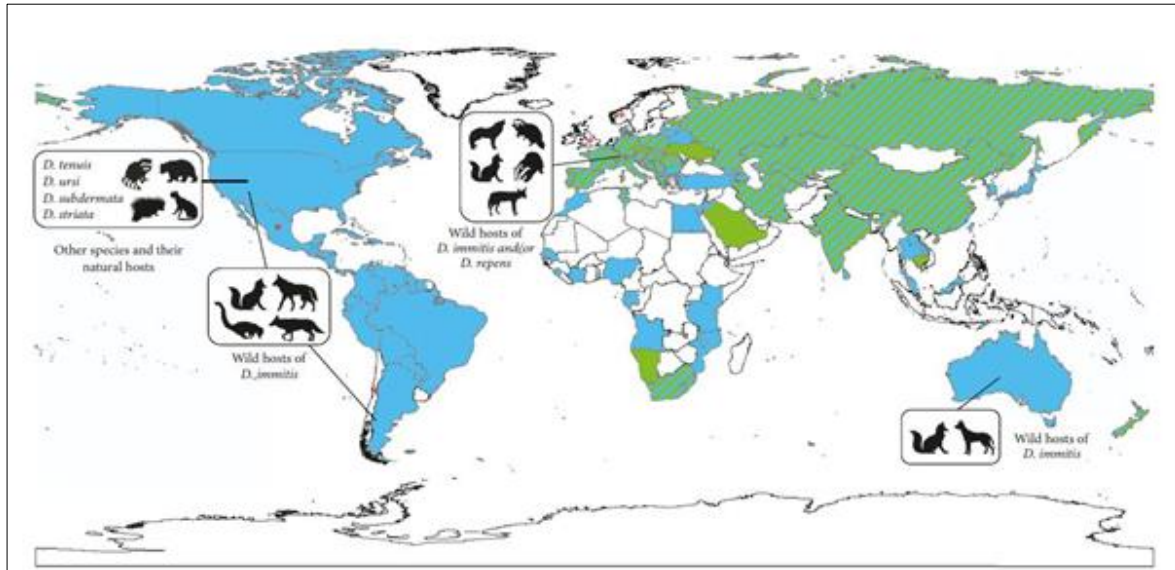
Emerging zoonoses are those diseases that are newly recognized or newly evolved or that has occurred previously but shows an increase in incidence or expansion in the geographic, host or vector range. Further, it affects the economy and health of particular region or country and other nations also. These zoonotic diseases are a group of diseases and infections which are naturally transmitted from vertebrate animals to man. Vector-borne zoonotic disease causes death and economic losses in human and domestic animal populations globally, hitting seriously the socio-economic development of developed and developing countries (Faburay, 2015; Day, 2011) [12, 11]. Dirofilariasis is one of the zoonotic parasitic diseases accidentally affecting the humans (dead-end host), caused by filarial nematodes of genus *Dirofilaria*, subgenus *Nochtiella* (Kini *et al.*, 2015) [19]. It infects various domestic and wild animals naturally and canines are the principal reservoir hosts (Reddy, 2013) [35]. Among nearly forty known species of *Dirofilaria* and at least six of them (*Dirofilaria immitis*, *Dirofilaria repens*, *Dirofilaria spectans*, *Dirofilaria tenuis*, *Dirofilaria striata* and *Dirofilaria ursi*) are known to cause accidental infections in humans (Horst, 2003) [14]. *D. repens* is the prevalent species identified in India. Mosquitoes of the genera *Aedes*, *Culex*, *Anopheles*, *Mansonia* and *Armigeres* species are reported to be associated in its transmission. Some classes of fleas, lice, and ticks are also supposed to act as vectors for dirofilariasis (Joseph *et al.*, 2011) [16]. Adult female *D. immitis* lays microfilariae, which are taken up by suitable mosquito vectors and finally develop to the infective 3rd larval stage. Transmission takes place when a likely vector bites dogs or other hosts during a subsequent blood meal. It takes about 6-7 months to shift into an adult stage. The symbiotic relationship with *Wolbachia* (Bacteriae) along with *D. immitis* magnifies disease severity (Morchón *et al.*, 2009) [25]. The main clinical signs include tenacious cough, dyspnoea and poor exercise tolerance followed by ascites, anorexia and weight loss. Globally there is greater attention and consideration of the increasing incidence and severity of human dirofilariasis infections. In India, at least one hundred subcutaneous/ocular and three pulmonary human cases had been reported (Kini *et al.*, 2015) [19]. Hence, this focuses a detailed review on dirofilariasis and its zoonotic potential.

Epidemiology

Human infection is often located in temperate, tropical, and subtropical areas of the world. So far, more than 1,700 human cases of dirofilariasis (including > 370 pulmonary cases) have been documented globally, implying that wherever canine dirofilariasis is present humans are

at higher risk (Montoya-Alonso *et al.*, 2010; Simon *et al.*, 2012) [24]. *Dirofilaria immitis* and *D. repens* are the most common species recorded in India (Sharma *et al.*, 2017) [38]. In India, the first case of human pulmonary dirofilariasis due to *D. immitis* was announced from Mumbai (Badhe and Sane, 1989) [2]. Most of the *D. immitis* human infections are asymptomatic exhibiting typical coin lesions on chest radiography and are often wrongly removed as neoplasm (Ciferri, 1982) [10]. The distribution of *D. immitis* spreads from the Pakistani border in the west, to Delhi and Sikkim in the north, to the border with Myanmar in the east and to Orissa to the south (Sabu *et al.*, 2005, Rani *et al.*, 2010) [37, 33], whereas that of *D. repens* incorporates central and western India (Mumbai), to Kerala in the south and as far north as Delhi (Rani *et al.*, 2010) [33]. The prevalence of *D. immitis* was

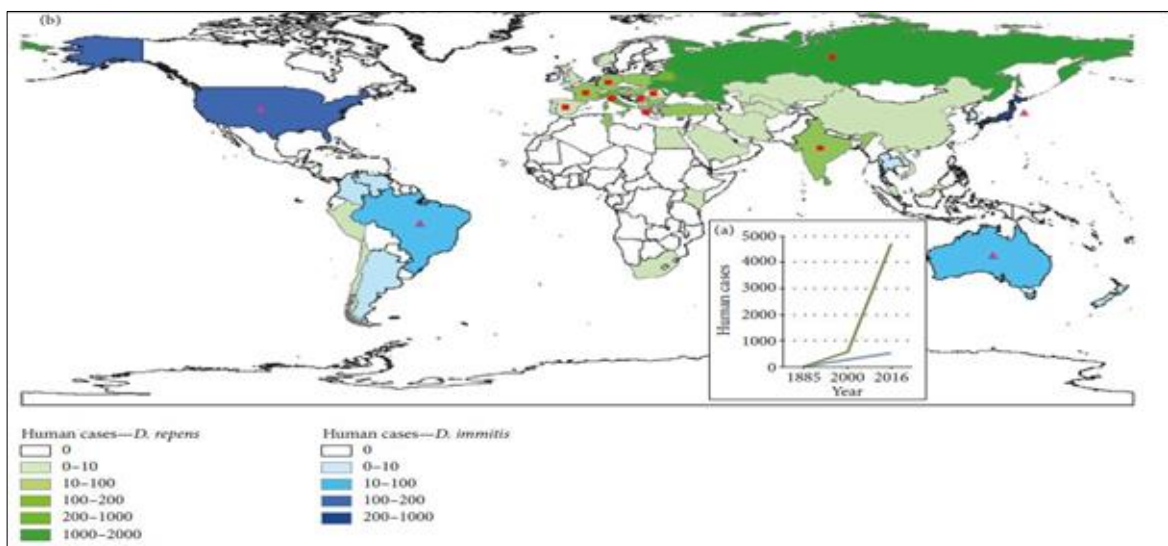
found to be 1%, 3%, 4%, 34% and 57% in Sikkim, Kolkata, Delhi, Mizoram and Orissa, respectively (Rani *et al.*, 2010; Chakravarty and Chaudhuri, 1983; Patnaik, 1989; Borthakur *et al.*, 2006) [33, 8, 30, 5], whereas that of *D. repens* was 5%, 7%, 17%, 14% and 21% in Delhi, Kerala, Mumbai, Orissa and Karnataka, respectively (Sabu *et al.*, 2005; Patnaik, 1989; Ananda *et al.*, 2006) [37, 30]. The first cases of human ocular and subcutaneous dirofilariasis was documented from Kerala in 1976 and 2004 respectively (Padmaja *et al.*, 2005; Joseph *et al.*, 1977) [29, 15]. In the past 2 years, cases of solitary subcutaneous dirofilariasis with *D. repens* were reported from Karnataka and Kerala. (Permi *et al.*, 2011; Bhat *et al.*, 2012) [31, 4]. Till now, two cases of zoonotic filariasis due to *D. tenuis* have been reported and both cases reported from southern part of India (Bhat *et al.*, 2012) [4].



D. immitis in pets (blue), *D. repens* in pets (green), *D. immitis* and *D. repens* in pets (striped); without information (white); (*) sporadic subcutaneous infections.

Source: The Complexity of Zoonotic Filariasis Ecosystem and Its Consequences: A Multidisciplinary View – (Simón *et al.*, 2017) [39]

Fig 1: Geographic distribution of the different species of *Dirofilaria* in the animal hosts in the world:



(a) - Geographic distribution of human dirofilariasis (reported cases), (b) - Pulmonary dirofilariasis (blue), subcutaneous/ocular dirofilariasis (green), sporadic cases of subcutaneous/ocular dirofilariasis in areas where pulmonary dirofilariasis predominates (fuchsia triangles), sporadic cases of pulmonary dirofilariasis in areas where subcutaneous/ocular dirofilariasis predominates (red squares).

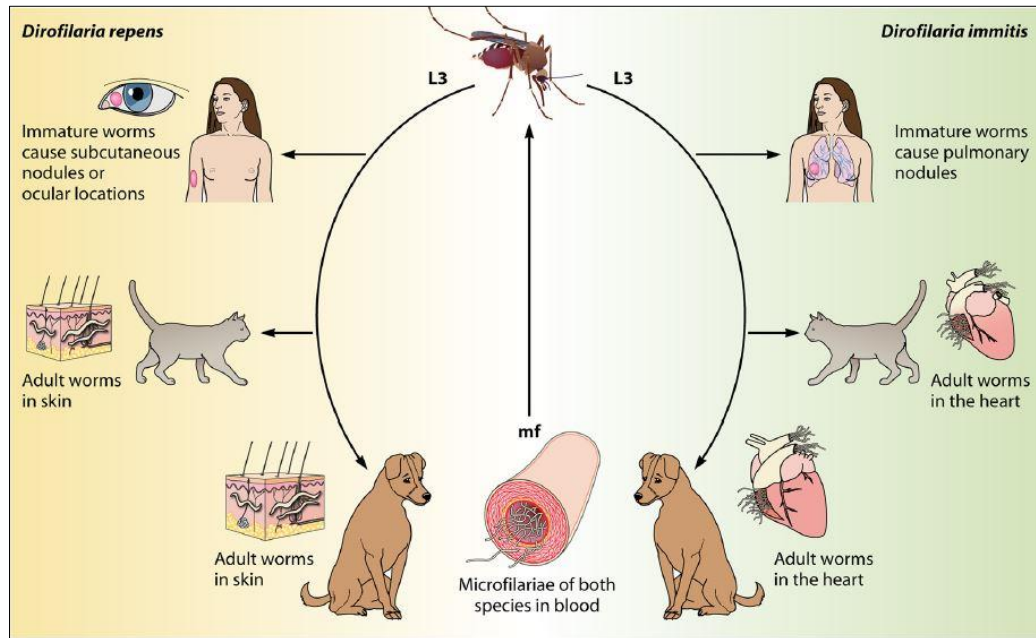
Source: The Complexity of Zoonotic Filariasis Ecosystem and Its Consequences: A Multidisciplinary View – (Simón *et al.*, 2017) [39]

Fig 2: Changes in the incidence of human dirofilariasis reported cases:

Life cycle

The life cycle of *Dirofilaria* species constitutes a definitive vertebrate host and a vector. The vectors are females of numerous mosquito species of the *Culicidae* family (Cancrini and Kramer, 2001) [6]. While a blood meal, mosquitoes deposit hemolymph on the wound, which conveys infectious "larvae 3" stage that enters the host's skin on their own (Venco *et al.*, 2011) [43]. The molt from L3 to L4 happens soon after *D. immitis* infection, between 3 to 12 days

postinfection (d.p.i.) and the succeeding molt, which produces preadult worms, takes place between 50 to 70 d.p.i. Both *D. immitis* and *D. repens* exhibit poor vertebrate host specificity given that they can infect numerous mammalian species (Barriga, 1982) [3]. Among mammalian hosts, they are best adapted to domesticated and wild dogs, which function as reservoirs. Humans and cats are less suitable hosts (McCall, 2008) [21], in which parasite development is dramatically altered compared with the patterns in dogs.



L3 – Larvae 3, mf – microfilaremia

Source: Human and Animal Dirofilariasis: the Emergence of a Zoonotic Mosaic – (Simón *et al.*, 2012) [41]

Fig 3: Life cycle of human dirofilariasis

Disease and clinical manifestation in humans

There are two classes of the disease: (1) Pulmonary dirofilariasis caused by *Dirofilaria immitis* (Dog heartworm) and (2) Subcutaneous dirofilariasis caused by *D. repens* and *D. tenuis*, parasites of the dog, cat and raccoon respectively. Unusually, parasite has also been recovered from deeper locations of the liver, breast, peritoneal cavity, omentum and ligament (Padmaja *et al.*, 2005; Kim *et al.*, 2002; Mrad *et al.*, 1999; Orihel and Eberhard, 1998) [29, 18, 26, 28]. Human dirofilariasis typically manifests as either subcutaneous nodules or as lung parenchymal disease. Patients affected with *D. repens* notice a subcutaneous lump in the affected area which most commonly involves; face and conjunctiva of the eye and sometimes chest wall, upper arms, thighs, abdominal wall and male genitalia. Ocular involvement is usually periorbital, orbital, subconjunctival, or subtenon infection (Chopra *et al.*, 2012) [9]. Human *D. immitis* infection has been associated with human pulmonary dirofilariasis and is usually asymptomatic. Those with symptoms have a cough, chest pain, fever and pleural effusion (Badhe and Sane, 1989) [2]. Clinically infection is apparent as a solitary subcutaneous nodule commonly in the head and neck region with or without pain.

Clinical manifestation in animals

Dogs reveal no indication of heartworm infection during the six-month prepatent period prior to the worm's maturation and modern diagnostic tests for the presence of microfilariae or antigens cannot identify prepatent infections. Rarely, migrating heartworm larvae get lost and end up in unusual

sites, such as the eye, brain, or an artery in the leg, which results in unusual symptoms such as blindness, seizures and lameness, but usually, until the larvae mature and congregate inside the heart, they produce no symptoms or signs of illness. Clinical signs such as coughing, exercise intolerance, unthriftiness, dyspnea, cyanosis, hemoptysis, syncope, epistaxis, and ascites (right-side CHF) may occur. The frequency and severity of clinical signs correspond to lung pathology and level of animal activity. Signs are often not observed in sedentary dogs, even though the worm load may be relatively high. Infected dogs undergoes a dramatic increase in activity, such as during hunting seasons, may develop overt clinical signs. Moreover, worm death and thromboemboli precipitate clinical signs. In the most advanced cases where many adult worms have built up in the heart without treatment, signs progress to severe weight loss, fainting, coughing up blood and finally, congestive heart failure.

Acute heartworm disease in cats can end in shock, vomiting, diarrhea, fainting, and sudden death. Chronic infection can induce loss of appetite, weight loss, lethargy, exercise intolerance, coughing and difficulty breathing. The signs of heartworm-associated respiratory disease can continue even after the complete exclusion of the heartworm infection (Yin, 2007) [44].

Diagnosis

Surgical excision of the worm and biopsy aids in both diagnosis and treatment. The morphological examination has flaws in the classification of the exact species as a huge

number of zoonotic *Dirofilaria* species have been reported that share morphologic features with *D. repens* (Poppert *et al.*, 2009) [32]. Distinguishing its characteristic longitudinal cuticular ridges by wet mount study or histopathological examination in conjunction with the characteristic clinical features is usually adequate for diagnosis in most of the cases (Orihel and Eberhard, 1998; Khurana *et al.*, 2010) [28, 17]. Laboratory diagnosis of dirofilariasis in live animals is constantly at the forefront in terms of demonstration and identification of microfilariae in the tested blood sample. Radiography and cardiography aid in the diagnosis of *D. immitis*, but the confirmatory and reliable diagnosis for heartworm disease is dependent on serology and molecular tests. Sometimes, in circulating blood of heartworm-infected dogs microfilariae are absent and such condition is termed as "Occult infection." In this case, obviously microscopy and PCR give false negative results. Several commercial ELISA based test kits are ready to diagnose heartworm in dogs but these kits are not extensively used in India. DNA based techniques contribute an alternative approach that is very sensitive and specific for identification of the filarial parasites (Rishniw *et al.*, 2006) [36]. The real attention of the medical profession is the lack of stable, non-invasive methods for the diagnosis of human dirofilariasis, particularly in the case of pulmonary lesions. It is difficult to distinguish radiologically a nodule by *Dirofilaria* from a likely malignant tumour (Genchi *et al.*, 2005) [13]. Definitive diagnosis is normally made with wedge biopsy, video-thoracoscopy or very rarely by fine needle biopsy (Milanez de Campos *et al.*, 1997) [23].

Treatment

The ultimate treatment of *Dirofilaria* infection in humans is the surgical removal of lung granulomas and subcutaneous nodules; this treatment is also curative. Chemotherapy is not recommended for human dirofilariasis (Simón *et al.*, 2012) [41]. The most crucial feature in the management of human dirofilariasis is its differentiation from other causes of nodules susceptible to being removed by surgery (Simón *et al.*, 2005) [40]. The symbiotic relationship between *Wolbachia* and numerous species of filariae, including *D. immitis* and *D. repens*, has provided promising new options for the treatment of filariasis using *Wolbachia* as a therapeutic target (Taylor *et al.*, 2001) [42] and these symbiotic *Wolbachia* bacteria are extremely sensitive to tetracyclines (McCall *et al.*, 2008) [21]. In case of canines, adulticidal therapy performed an important breakthrough in the management of heartworm infection is the adulticide melarsomine, an organoarsenical superior in safety and efficacy to thiacetarsamide (Knight *et al.*, 1992) [20]. Corticosteroids are indicated as ancillary therapy in heartworm infection only in the face of pulmonary parenchymal complications to treat or prevent adverse reactions to microfilaricides and possibly to reduce tissue reaction to melarsomine (Rawlings *et al.*, 1983) [34]. Microfilaria is efficiently and immediately cleared with ivermectin or with milbemycin (Nelson *et al.*, 2005) [27].

Prevention and control

Preventing infection in dogs can be done by daily administration of diethylcarbamazine during and after heartworm season. The introduction of the macrolide agents such as ivermectin, milbemycin, moxidectin and selamectin has provided the veterinary profession with effective heartworm preventatives in a variety of formulations. Such agents, because they interrupt larval development during the first two months after infection, have a large window of

efficacy and are administered monthly or less frequently and these agents are superior to diethylcarbamazine (McCall *et al.*, 1996) [22]. Macrocyclic lactone is a parasiticide that prevents heartworm as well as other intestinal and external parasites. This reduces new infections by reducing the number of microfilariae circulating in peripheral blood of canines available for consumption by vectors.

Dirofilariasis can be prevented by avoiding mosquito bites in areas where vectors may be infected with *Dirofilaria* larvae. The risk of such mosquito bites can be reduced by leaving as little skin exposed as possible, by the use of insect repellent when exposed to vectors and by sleeping under an insecticide-treated bed net in areas where *Dirofilaria*-infected vectors bite at night and have access to sleeping areas (CDC, 2012) [7]. Walking dogs earlier in evening before mosquitoes become active also reduces the number of bites.

Reduce mosquito vector populations in urban areas by using mosquito larvicides or biological control like larvae-eating fish species.

Conclusion

Animal and human health is united today into a One Health concept, which concentrates on zoonotic pathogens emerging from companion animals, domestic animals and wildlife. An alarming increase in the trend of dirofilariasis in the past few years points towards a call for the required action to be taken towards the control of this infection. Succeeding of canine vector-borne diseases requires a One Health approach and precise control of arthropod-transmitted pathogens to both human beings and animals. This strategy is only achievable when clinicians and researchers from multi sectors should act together. Developing suitable molecular diagnostic tools for identification of species, systematic epidemiological surveys and concentrated studies on natural hosts, vectors and environmental factors will support in the appraisal of the exact prevalence of this emerging zoonotic dirofilariasis and in devising relevant control measures.

References

- Ananda KJ, D'Souza PE, Jagannath MS. Methods for identification of microfilaria of *Dirofilaria repens* and *Dipetalonema reconditum*. J Vet. Parasitol. 2006; 20(1):45-47.
- Badhe BP, Sane SY. Human pulmonary dirofilariasis in India: A case report. J Trop. Med. Hyg. 1989; 92:425-6.
- Barriga OO. Dirofilariasis, In Steele JH, Schultz MG (ed), Handbook series in zoonoses. 1982; 2:93-110.
- Bhat S, Sofia O, Raman M, Biswas J. A case of subconjunctival dirofilariasis in South India. J Ophthalmic Inflamm. Infect. 2012; 2:205-6.
- Borthakur SK, Sarmah K, Rajkhowa TK, Das MR, Rahman S. *Dirofilaria immitis* infection in dog. J Vet. Parasitol. 2006; 20:167-169.
- Cancrini G, Kramer LH. Insect vectors of *Dirofilaria* spp. *Heartworm infection in humans and animals*, Ediciones Universidad de Salamanca, España. 2001, 63-82p.
- CDC. Dirofilariasis. Centers for Disease Control and Prevention.gov, 2012.
- Chakravarty A, Chaudhuri MN. Studies on canine filariasis in West Bengal. Ind. J Anim. Hlth. 1983; 22:151-155.
- Chopra R, Bhatti SM, Mohan S, Taneja N. *Dirofilaria* in the anterior chamber: A rare occurrence. Middle East Afr. J Ophthalmol. 2012; 19(3):49-51.

10. Ciferri F. Human pulmonary dirofilariasis in the United States: a critical review. *Am. J Trop. Med. Hyg.* 1982; 31(2):302-308.
11. Day MJ. One health: the importance of companion animal vector-borne diseases. *Parasit. Vectors.* 2011; 4(1):49.
12. Faburay B. The case for a 'one health' approach to combating vector-borne diseases. *Infect. Ecol. Epidemiol.* 2015; 5(1):28132.
13. Genchi C, Simon F, Kramer LH. Dirofilariasis in humans: is it a real zoonotic concern. In Proceedings of the 30th World Congress of the World Small Animal Veterinary Association, 2005, 11-14p.
14. Horst A. *Dirofilaria* and dirofilarioses; Introductory remarks; In Proceedings of Helminthological Colloquium. Vienna, 2003.
15. Joseph A, Thomas PG, Subramaniam KS. Conjunctivitis by *Dirofilaria conjunctivae*. *Indian J Ophthalmol.* 1977; 24:20-2.
16. Joseph E, Matthai A, Abraham LK, Thomas S. Subcutaneous human dirofilariasis. *J Parasitol. Dis.* 2011; 5:140-143.
17. Khurana S, Singh G, Bhatti HS, Malla N. Human subcutaneous dirofilariasis in India: A report of three cases with brief review of literature. *Ind. J Med. Microbiol.* 2010; 28:394-396.
18. Kim MK, Kim CH, Yeom BW, Park SH, Choi SY, Choi JS. The first human case of hepatic dirofilariasis. *J Korean Med. Sci.* 2002; 17:686-690.
19. Kini RG, Leena JB, Shetty P, Lyngdoh RH, Sumanth D, George L. Human dirofilariasis: an emerging zoonosis in India. *J Parasitic Dis.* 2015; 39(2):349-354.
20. Knight DH. How Current Knowledge Has Affected the Diagnosis, Prevention, and Treatment of Heartworm Infection. In Soll, M.D, ed. *Proc Amer Heartworm Sym '92.* Austin, TX: AHS, 1992, 253p.
21. McCall JW, Genchi C, Kramer LH, Guerrero J, Venco L. Heartworm disease in animals and humans. *Adv. Parasitol.* 2008; 66:193-285.
22. McCall JW, McTier TL, Ryan WG, Gross SJ, Soll MD. Evaluation of ivermectin and milbemycin oxime efficacy against *Dirofilaria immitis* infections of three and four months' duration in dogs. *Am. J of Vet. res.* 1996; 57(8):1189-1192.
23. Milanez de Campos JR, Barbas CSV, Filomeno LTB, Fernandez A, Minamoto H, Filho JVB *et al.* Human Pulmonary Dirofilariasis Analysis of 24 Cases From Sao Paulo, Brazil. *Chest.* 1997; 112:729-33.
24. Montoya-Alonso JA, Mellado I, Carretón E, Cabrera-Pedrero ED, Morchón R, Simón F. Canine dirofilariosis caused by *Dirofilaria immitis* is a risk factor for the human population on the island of Gran Canaria, Canary Islands, Spain. *Parasitol. Res.* 2010; 107(5):1265-1269.
25. Morchón R, Simón F, González-Miguel J, Mellado I. Relationship *Dirofilaria*/hosts: cellular and molecular mechanisms of the heartworm disease vascular pathology. *SEDD*, 2009, 124p.
26. Mrad K, Romani-Ramah S, Driss M, Bougrine F, Hechiche M, Maalej M. Mammary Dirofilariasis: A case report. *Int. J Surg. Pathol.* 1999; 7:175-178.
27. Nelson CT, McCall JW, Rubin SB, Buzhardt LF, Dorion DW, Graham W *et al.* Guidelines for the diagnosis, prevention and management of heartworm (*Dirofilaria immitis*) infection in dogs. *Vet. parasitol.* 2005; 133(2-3):255-266.
28. Orihel TC, Eberhard ML. Zoonotic Filariasis. *Clin. Microbiol. Rev.* 1998; 11(2):366-381.
29. Padmaja P, Kanagalakshmi Samuel R, Kuruvilla PJ, Mathai E. Subcutaneous dirofilariasis in southern India: A case report. *Ann. Trop. Med. Parasitol.* 2005; 99:437-40.
30. Patnaik MM. On filarial nematodes in domestic animals in Orissa. *Ind. Vet. J.* 1989; 66:573-574.
31. Permi HS, Veena S, Prasad HK, Kumar YS, Mohan R, Shetty KJ. Subcutaneous human dirofilariasis due to *Dirofilaria repens*: Report of two cases. *J Glob. Infect. Dis.* 2011; 3:199-201.
32. Poppert S, Hodapp M, Krueger A, Hegasy G, Niesen WD, Kern WV *et al.* *Dirofilaria repens* infection and concomitant meningoencephalitis. *Emerg. Infect. dis.* 2009; 15(11):1844.
33. Rani PAMA, Irwin PJ, Gatne M, Coleman GT, McInnes LM, Traub RJ. A survey of canine filarial diseases of veterinary and public health significance in India. *Parasit. Vectors.* 2010; 3:30.
34. Rawlings CA, Keith JC, Schaub RG. Post Adulticide Treatment Pulmonary Disease and its Modification with Prednisolone and Aspirin. In Otto GF, ed. *Proc Amer Heartworm Sym '83,* Edwardsville, KS: Veterinary Medical Publishing Co., 1983, 122p.
35. Reddy MV. Human dirofilariasis: An emerging zoonosis. *Trop. parasitol.* 2013; 3(1):2.
36. Rishniw M, Barr SC, Simpson KW, Frongillo MF, Franz M, Alpizar JLD. Discrimination between six species of canine microfilariae by a single polymerase chain reaction. *Vet parasitol.* 2006; 135(3-4):303-314.
37. Sabu L, Devada K, Subramanian H. Dirofilariosis in dogs and humans in Kerala. *Ind. J Med. Res.* 2005; 121(5):691-693.
38. Sharma R, Singh BB, Gill JPS, Jenkins E, Singh B. Canine parasitic zoonoses in India: status and issues. *Revue scientifique et technique* (International Office of Epizootics). 2017; 36(3):817-830.
39. Simón F, González-Miguel J, Diosdado A, Gómez PJ, Morchón R, Kartashev V. The complexity of zoonotic filariasis epistystem and its consequences: a multidisciplinary view. *Biomed. Res. Int.* 2017.
40. Simón F, López-Belmonte J, Marcos-Atxutegi C, Morchón R, Martín-Pacho JR. What is happening outside North America regarding human dirofilariasis? *Vet. Parasitol.* 2005; 133:181-189.
41. Simón F, Siles-Lucas M, Morchón R, González-Miguel J, Mellado I, Carretón E *et al.* Human and animal dirofilariosis: the emergence of a zoonotic mosaic. *Clin. Microbiol. Rev.* 2012; 25(3):507-544.
42. Taylor MJ, Cross HF, Ford L, Makunde WH, Prasad GBKS, Biló K. *Wolbachia* bacteria in filarial immunity and disease. *Parasite Immunol.* 2001; 23(7):401-409.
43. Venco L, Genchi C, Simón F. La filariosis cardiopulmonar (*Dirofilaria immitis*) en el perro, 2011, 19-60p.
44. Yin S. Update on heartworm infection. In *Vet Forum*, 2007, 42-43p.