



E-ISSN: 2278-4136
P-ISSN: 2349-8234
www.phytojournal.com
JPP 2020; 9(3): 205-212
Received: 18-03-2020
Accepted: 22-04-2020

Ozioko Onyinye Mary

Department of Anatomy, College
of Medicine, Enugu State
University of Science and
Technology, Enugu, Nigeria

Ozioko Uche Sebastine

Department of Anatomy, College
of Medicine, Enugu State
University of Science and
Technology, Enugu, Nigeria

Mba Christian Ejuiwa

Department of Anatomy, College
of Medicine, Enugu State
University of Science and
Technology, Enugu, Nigeria

Ozor Ignatius Ikemefuna

Department of Anatomy, College
of Medicine, Enugu State
University of Science and
Technology, Enugu, Nigeria

Egwatu Dominic

Department of Anatomy, College
of Medicine, Enugu State
University of Science and
Technology, Enugu, Nigeria

Corresponding Author:**Mba Christian Ejuiwa**

Department of Anatomy, College
of Medicine, Enugu State
University of Science and
Technology, Enugu, Nigeria

Anxiolytic and curative effect of *Solanum macrocarpon* leaves extract on acetaminophen induced brain injury in adult Wistar rats

Ozioko Onyinye Mary, Ozioko Uche Sebastine, Mba Christian Ejuiwa, Ozor Ignatius Ikemefuna and Egwuatu Dominic

Abstract

Background of study: Herbal plants such as *Solanum macrocarpon* may have free radical scavenging activity and is used in the treatment of brain tissue hence this study was aimed at investigating the effect of aqueous extract of *solanum macrocarpon* leaf on acetaminophen induced brain injury.

Materials and Method: Twenty- four adult male wistar rats with average age of 120-215 grams were purchased and used for this experiment. The rats were divided into six (6) groups of four (4) rats each. After 14days of acclimatization, the rats were grouped into control group (group A) and experimental groups (group B, C, D, E and F). The control group were given normal saline and feed. Group B rats were given 0.5ml of acetaminophen with 200mg/kg of aqueous extract. Group C received 0.5 ml of acetaminophen with 400mg/kg of aqueous leaf extract. Group D received 0.5ml of acetaminophen with 600mg/kg of aqueous leaf extract while Group E received 0.5ml of acetaminophen only. Group F were given standard drug, vitamin E orally for 10 days. The animal sacrificed on the 20THday, and the organ was harvested for assaying brain function and histopathological test. Brain tissues were excised and fixed in formal saline then processed using the Hematoxylin and Eosin method.

Result: Administrations of aqueous leaf extract of *S. macrocarpon* shows moderate healing with mild condensed neurons (CN), mild microcytic space (MS) and some plasma cell (PC) secondary to acetaminophen (H/E) X (400) induced cortex degeneration with microcystic space (MS), shrinking of the neurons (SN), eosinophilic substance within the vacuolated space (ES) and moderate coagulative necrosis.

Conclusion: This present study proved that the aqueous extract of *Solanum macrocarpon* leaf exhibited a dose dependent significant antioxidant property on the brain against acetaminophen induced inflammation on the experiment rats. It is however recommended that further investigations should be carried on the efficacy and safety of use this extract on the brain and other tissues before recommending its use for certain medicinal.

Keywords: Anxiolytic, *Solanum macrocarpon*, acetaminophen induced brain, Wistar rats

Introduction

Solanum macrocarpon also known as the African eggplant or Gboma is a plant that belongs to the Solanaceae family and is popularly consumed as edible tropical perennial plant that is closely related to the eggplant. (Oboh *et al.*, 2005) [6, 10].

Studies have shown that the leaves are rich in protein, fat, crude fiber, calcium, zinc (Oboh *et al.*, 2005) [6, 10] and have gastric medicinal benefits (Bukanya-Ziraba and Bonsu, 2004) [7]. The leaves of *Solanum macrocarpon* also aid in treatment of constipation, ulcers, tooth ache and is also a snake bite antidote (Oladiran, 1989) [11]. It is used in treatment of skin diseases, infections and sores (Edijala *et al.*, 2005) [9]. Generally, the plant has been used as an indigenous medicine for the treatment of several ailments such as asthma, allergic rhinitis, nasal catarrh, skin infections, rheumatic disease and swollen joint pains, gastro-esophageal reflux disease, constipation, dyspepsia and also in weight reduction (Dalziel, 1937). The aqueous fruit extract of the plant, has also been reported to exhibit lipid lowering activities as well as renal and hepatoprotective effects in diet-induced hypercholesterolemic rats (Sodipo *et al.*, 2009a,b; Sodipo *et al.*, 2009c, 2011b) [18, 15, 19], high phenolic and flavonoid content, thus possessing a potent antioxidant activity which can offer good protection against oxidative damage to some body tissues (Adewale *et al.*, 2014) [12, 20, 41].

The protective effect of the antioxidant compounds in *Solanum macrocarpon* leaves have demonstrated high electron donating capacity which initiates chain termination in the lipid peroxidation mechanism and transforming reactive free-radical species into more stable nonreactive products, hence can offer good protection against oxidative damage to body cells,

particularly liver and brain (Olusola *et al.*, 2014)^[12, 20].

Drug abuse has been shown to cause structural and functional disorders in prefrontal cortex and invariably impaired cognitive control (Charle *et al.*, 2014).

Paracetamol first made in 1877, (Mangus *et al.*, 2005)^[25] also known as acetaminophen /APAP is enlisted on the World Health Organization's List of Essential Medicines, (World Health Organization Model list of Essential Medicines 2019)^[27] and available as a generic medication with trade names including Tylenol and Panadol, among others. (Hamilton *et al.*, 2013).

Paracetamol is generally safe at recommended doses (Russell *et al.*, 2003)^[22] and frequently used to treat pain and fever. (American Society of Health –System pharmacist *et al.*, 2016)^[21]. The recommended maximum daily dose for an adult is four grams (Lewis *et al.*, 2013)^[23]. Although it is classified as a mild analgesic, paracetamol does not have significant anti-inflammatory activity. (McKay *et al.*, 2013)^[24].

Paracetamol apparently might modulate the endogenous cannabinoid system in the brain through its metabolite, AM404, which appears to inhibit the reuptake of the endogenous cannabinoid/vanilloid anandamide by neurons, making it more available to reduce pain. AM404 also appears to be able to directly activate the TRPV1 (older name: vanilloid receptor), which also inhibits pain signals in the brain (Ghanem *et al.*, 2016)^[34].

Pharmacokinetics

After being taken orally, paracetamol is rapidly absorbed by the gastrointestinal (GI) tract. (Prescott *et al.*, 1980)^[28] and its volume of distribution is roughly 50 L. (Graham *et al.*, 2013)^[29]. The concentration in serum after a typical dose of paracetamol usually peaks below 30 µg/ml (200 µmol/L). After 4 hours, the concentration is usually less than 10 µg/ml (66 µmol/L).. (Marx *et al.*, 2013)^[30].

Paracetamol is metabolized primarily in the liver, into toxic and nontoxic products. Mehta *et al.*, (2012)^[33] have noted three metabolic pathways namely Glucuronidation (45-55%), Sulfation (Sulfate conjugation) (20-30%) (Fortuny *et al.*

2006)^[35], N-hydroxylation and dehydration, then glutathione conjugation, (less than 15%). (Ronald *et al.*, 1995)^[31].

All three pathways yield final products that are inactive, nontoxic, and eventually excreted by the kidneys. In the third pathway, however, the intermediate product NAPQI is toxic. NAPQI is primarily responsible for the toxic effects of paracetamol; this constitutes an example of toxication (Brayfield *et al.* 1995)^[32].

Methods

Animal Management and Grouping

30 healthy adult male wister rats (weighing about 120-210g). The animals were housed in Plastic cages with iron nettings and maintained under standard laboratory conditions (Temperature 24 °C ± 2 °C, with relative humidity of 60-70% under 12hours light and dark cycles) and were provided easy access to food (growers mesh) and water *ad libitum*.

The animals were allowed to acclimatize for two weeks prior to the experiment. At the end of the acclimatization, twenty-four (24) were selected randomly and divided into (6) groups of four (4) animals each. They were labeled group 1-6 which group 1 served as the control group. The body weight were obtained using an electronic weighing scale before and after acclimatization, and also continued at weekly intervals during the experiment.

Animal Treatment

Group A received water and feed (positive control group), group B received 550mg/kg¹ of acetaminophen and 100mg/kg¹ of *Solanum macrocarpon* (low dose), group C received 550mg/kg¹ of acetaminophen and 200mg/kg¹ of *Solanum macrocarpon* (middle dose), group D received 550mg/kg¹ of acetaminophen and 400mg/kg¹ of *Solanum macrocarpon*(high dose), group E received 550mg/kg¹ of acetaminophen only (negative control group) while group F received 550mg/kg¹ of acetaminophen and 50mg/kg¹ of vitamin E. Acetaminophen induced nephrotoxicity period lasted for ten (10) days followed by another ten (10) days of oral administration of *Solanum macrocarpon* extract.

Table 1: Summary of animal grouping Administration of 24 rats of (210±20g)

Group	No of rat	Total duration	Induced substance (pcm)	Dosage	Treatment	Duration of administration of drug	Duration of administration of extract
Group a	4 rat	20 days	Nil	Nil	Nil	Nil	Nil
Group b	4 rat	20 days	550mg	100mg	Extract low dose	10 days	10 days
Group c	4 rat	20 days	550mg	200mg	Extract medium dose	10 days	10 days
Group d	4 rat	20 days	550mg	400mg	Extract high dose	10 days	10 days
Group e	4 rat	20 days	550mg	Nil	Nil	10 days	Nil
Group f	4 rat	20 days	550mg	50mg	Vitamin E	10 days	10days

Collection of brain tissue (Cerebral cortex)

Under diethyl ether anesthesia, animals of each group were sacrificed on the 20th day, and the brain was harvested and fixed in 10% formalin (Dougnon *et al.*, 2009) in a sample bottle with tight fitting lids for 72 hours as a prelude to improve staining quality and to aid optical differentiation of cell contents.

Tissue preparation for microscopy: The tissue were subsequently trimmed, dehydrated in ascending grades of alcohol (70%,80%,90% and absolute alcohol), cleared in three (3) changes of xylene and embedded in molten paraffin wax. Sections of 5µm thickness with a rotary microtome were made, floated in water bath (45°C) and incubated at 60 °C to dry. The 5µm thick sections were subsequently stained in

using hematoxylin and Eosin stains. The photomicrographs were taken using a moticTM5.0 megapixels microscope camera.

Results

Behavioral Tests: Y- Maze test (YMT) and elevated plus maze test (EPM) were carried out in this study. The tests were performed before, during and after administration of acetaminophen in days 0, 15 and 22. Behavioral tests were performed 24 hours after a previous acetaminophen administration so as to allow time for drug distribution that may be used to access possible behavioral changes that may be caused by acetaminophen absorption in the blood stream. (Yoon *et al.* 2016, Ferri, Fred F. (2016).)^[1, 2]. All behavioral tests were recorded with a camcorder and manually timed.

Y – Maze Test

This test is used to access spatial working memory. Arm entries are counted. An arm entry is when all four legs of the rat are completely in the arm. Spontaneous alternation was also counted. Spontaneous alternation is when an animal enters three different arms consecutively in triple sets. Percentage of alternation was calculated as {spontaneous alternation/ (total number of arm entries – 2)} * 100 (Reza, *et al.*,2009) [3] Each rat was placed in the Y maze apparatus for 5 minutes after which the apparatus was cleaned with 5% ethanol to clean up any possible odour left by the last animal before introducing another.

Elevated Plus Maze Test

Elevated Plus Maze (EPM) is used to access the rate of anxiety in laboratory rodents (Sun, *et al.*,2008) [4]. The EPM apparatus look like a plus sign with two open arms (50cm X 10cm) and two closed arms in opposite directions. The walls of the closed arms are 30cm high and the maze is elevated 60 cm above the floor. The open arms contain a slight ledge (4 mm high) to prevent the rats from slipping and falling off the edge. The central square is 5cm X 5cm. Each rat was placed in the centre of the elevated plus maze facing an open arm, and allowed 5 minutes to freely explore the apparatus. The following parameters were measured: open arm entries, time spent in open arms, closed arm entries, time spent in close arms and total arm entries. Arm entry is defined as when the hind paws of the rats are completely within the arm. The closed arms provide a sense of safety because they are enclosed. Behaviors such as open arm activity and head dipping are considered exploratory, and a greater frequency of these activities shows a greater level of exploration (Brown, *et al.*, 1999) [5].

Statistical analysis

All behavioral tests were carried out using one way ANOVA and Bonferroni post test. Data for each experimental group were analyzed and compared with the control group. Graphpad prism version 5.03, Graph pad.

Results

Behavioural test

Results for elevated plus maze test

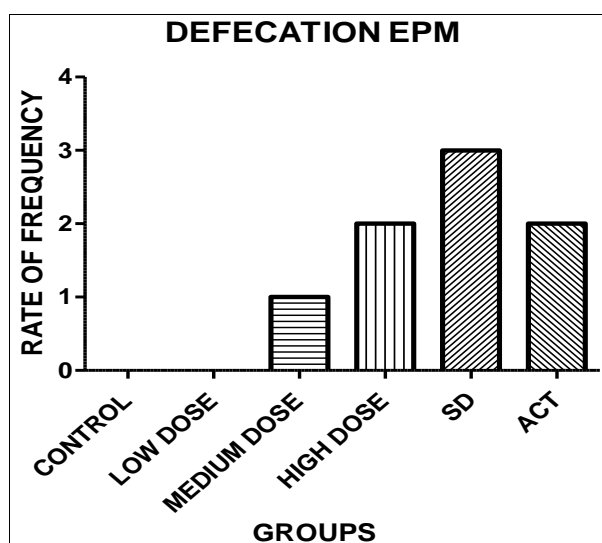


Fig 1: Result showing animals response to fear which shows in the amount of fecal boil deposited during test. Results did not show any significant difference in comparison of fecal boil deposits. $P = 0.0467$ with $P \leq 0.05$. Not statistically significant. (Kruskal Wallis Test)

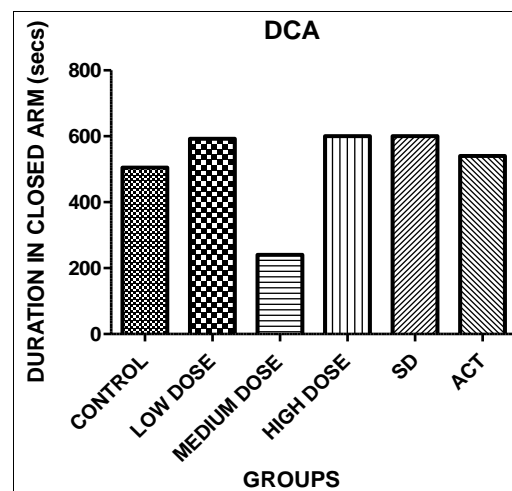


Fig 2: Result showing duration of animals in the closed arm (DCA) of the elevated plus maze. Medium dose group showed the least time spent in the closed arm. $P = 0.4159$. Test result was not statistically significant with 0.05 as level of significance. (Kruskal Wallis Test)

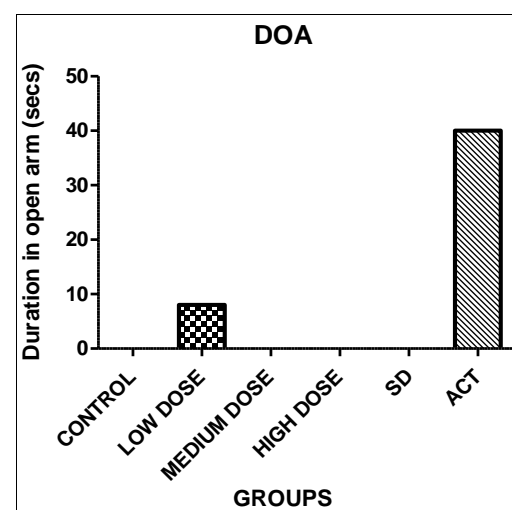


Fig 3: Result showing duration of animals in the open arm (DOA) of the elevated plus maze test. Only low dose and act groups showed activity in the open arm with $p = 0.4239$. Test result was not statistically significant with 0.05 as level of significance. (Kruskal Wallis Test)

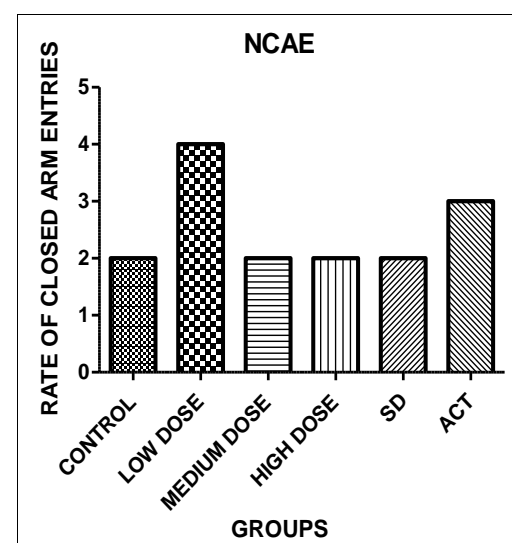


Fig 4: Result showing rate at which animals entered the close arm of the elevated plus maze across the groups. Number of Closed Arm Entries (NCAE). Animals in the low dose group made more entries into the closed arm depicting high levels of anxiety. $P = 0.3123$. However, test result was not statistically significant with 0.05 as level of significance. (Kruskal Wallis Test)

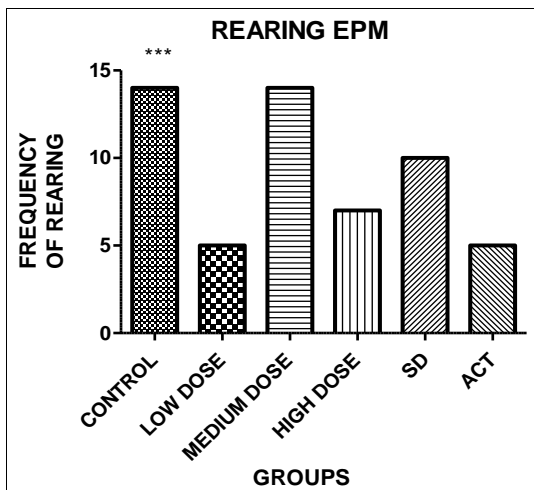


Fig 5: Showing frequency of rearing displayed by the animals across the groups with the control and medium dose groups displaying more exploratory behavior. $P=0.4159$ with $P \leq 0.05$. (Kruskal Wallis Test)

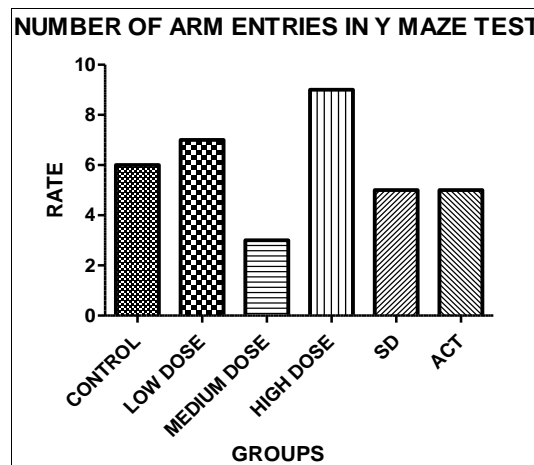


Fig 8: Y maze result showing the number of arm entries made by animals across the groups. More arm entries indicate high loco motor activity. High dose group indicated high loco motor activity followed by the low dose group. This is an indication of intense psychomotor activity with p value at 0.2124. Results showed no significant difference in the number of entries made with level of significant at 0.05. (Kruskal Wallis Test)

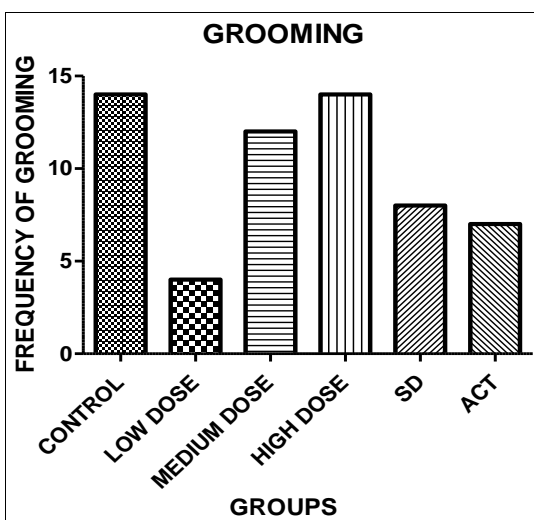


Fig 6: Showing grooming activity of animals across groups with control and high dose groups displaying more response to novelty and possible stress. $P = 0.4159$ with $P \leq 0.05$. Not statistically significant. (Kruskal Wallis Test)

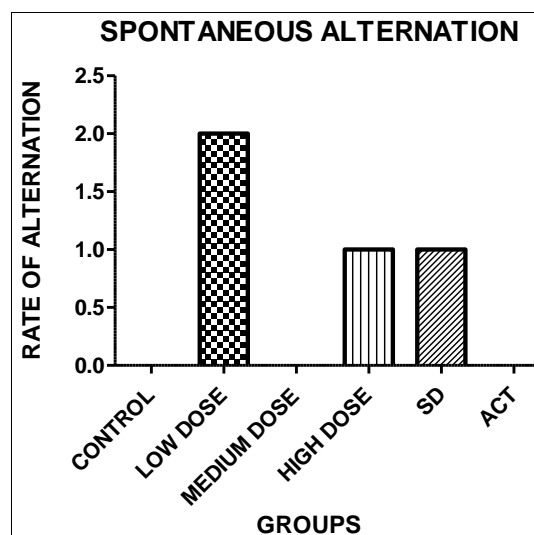


Fig 9: Y maze result showing level of spontaneous alternation showed by animals across the groups. It shows the willingness of the animals to explore new environments. The low dose group of animals showed marked willingness to explore with p value at 0.2134. Results showed no significant difference in willingness to explore new environments with 0.05 as level of significance. (Kruskal Wallis Test)

Results for y maze test

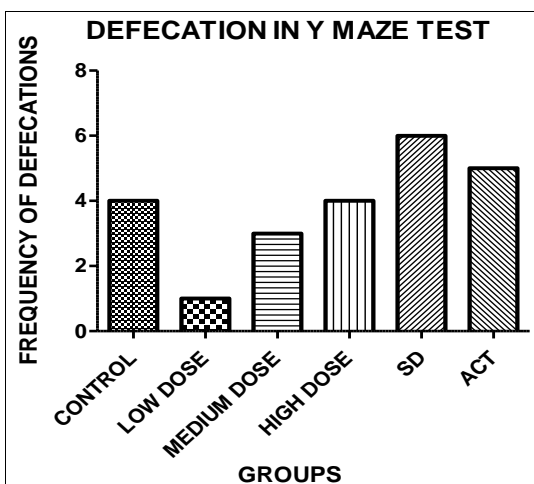


Fig 7: Y maze result showing frequency of deposition of fecal boil by the animals across the groups with high level of anxiety recorded by animals in the sd group. Animals in the low dose group showed the lowest level of anxiety with low fecal boil deposits. $P= 0.4123$. Test result showed no significant difference in anxiety levels across the groups with 0.05 as level of significance. (Kruskal Wallis Test)

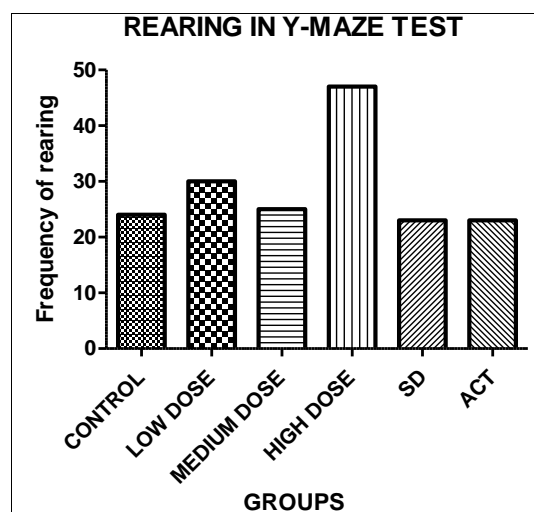


Fig 10: Showing rearing activity amongst animals across the groups. Animals in high dose groups displayed more exploratory activity. $P=0.4159$ with $P \leq 0.05$. Not statistically significant. (Kruskal Wallis Test)

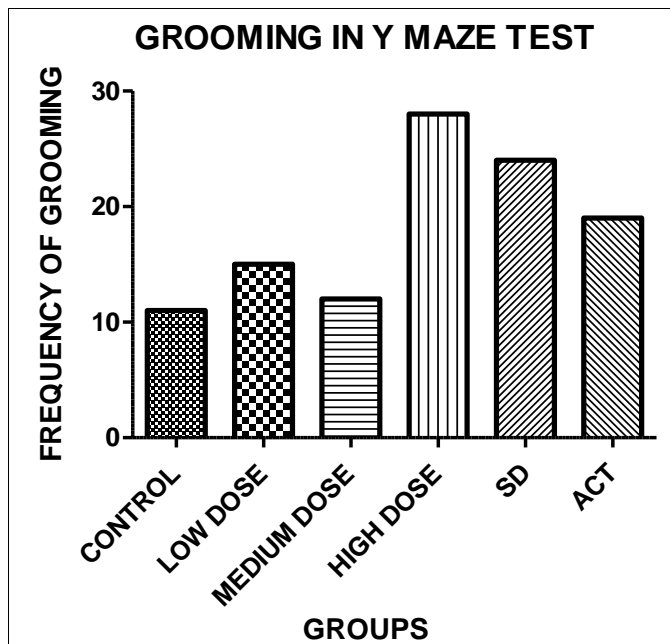


Fig 11: Showing animals response to novelty and possible stress with the high dose group displaying more grooming activity. $P=0.4257$ with $P \leq 0.05$, statistically significant (Kruskal Wallis Test)

Histological findings

Group A (CONTROL GROUP)

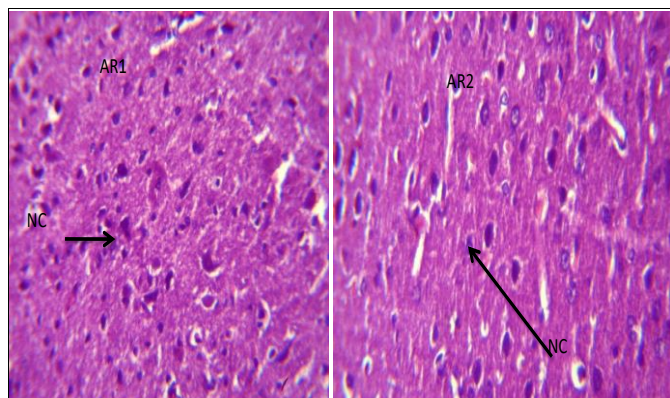


Plate 1: Photomicrograph of the cerebral cortex showing normal neural cell bodies in the gray matter (NC) (H & E. X400)

Group B

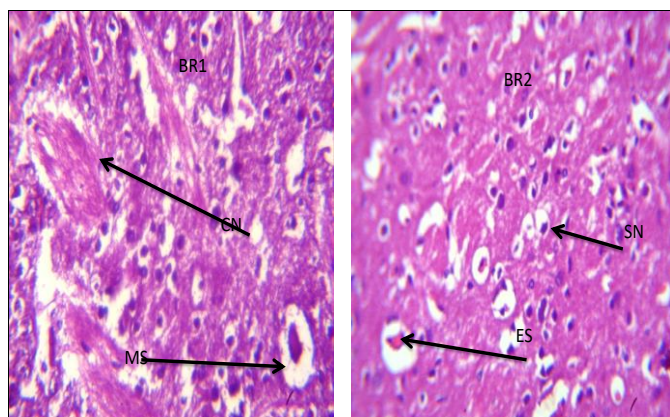


Plate 2: Photomicrograph of cerebral cortex induced with 550mg/kg of acetaminophen and 100mg/kg *Solanum macrocarpon* extract showing mild/moderately condensed neurons (CN) and moderate microcytic spaces (MS). (H & E. X400)

Group C

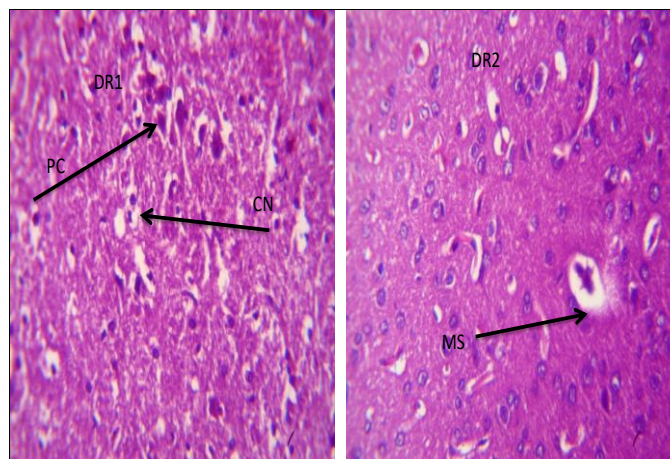


Plate 3: Photomicrograph of cerebral cortex induced with 550mg/kg of acetaminophen and 200mg/kg of *Solanum macrocarpon* showing moderate healing with mildly condensed neurons (CN) and mild microcytic space (MS) (H & E. X400)

Group D (High dose)

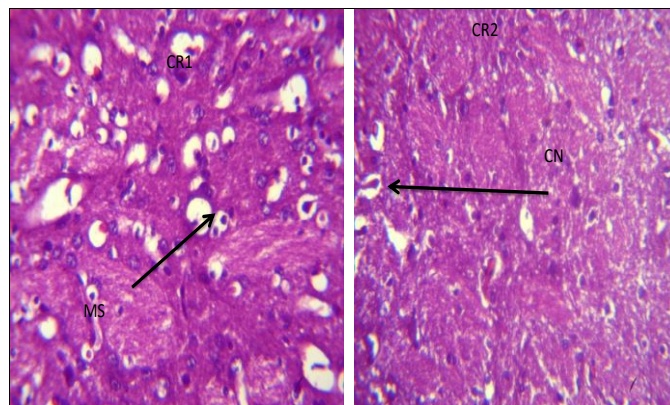


Plate 4: Sections of cerebral cortex induced with 550mg/kg of acetaminophen and 400mg/kg *solanum macrocarpon* shows moderate healing with mild condensed neurons (CN), mild microcytic space (MS). H & E. X400

Group E

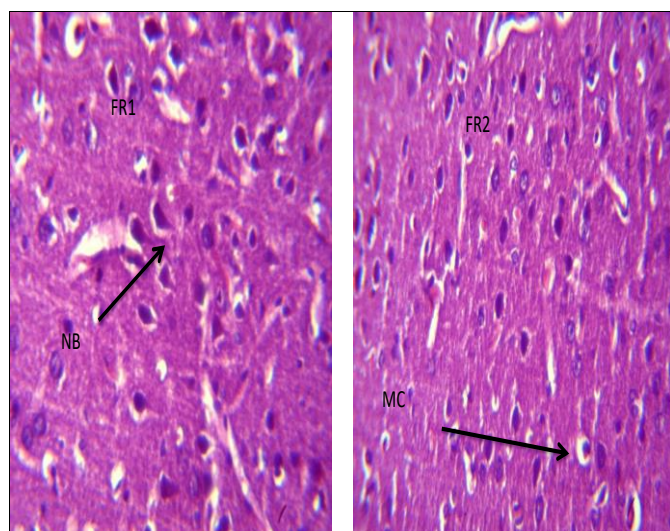


Plate 5: Photomicrograph of cerebral cortex induced with 550mg/kg of acetaminophen and vitamin E showing moderate healing with mild microcytic spaces (MS). H & E. X400

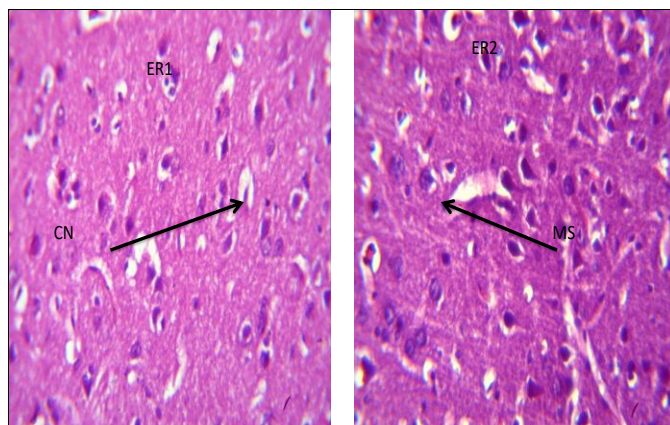
Group F

Plate 6: Photomicrograph of the cerebral cortex induced with 550mg/kg of acetaminophen showing moderate degeneration with microcystic space (MS), shrinking of the neurons (SN) moderate coagulative necrosis (ES) and eosinophilic substance within the vacuolated space (ES). H & E. X400.

Discussion

This work was aimed at investigating the curative effect of *solanum macrocarpon* leaves extract on acetaminophen induced brain injury in adult wistar rats. All animals except control group were given 550mg/kg of acetaminophen. Result On the present study indicates that there was no significant change on anxiety levels amongst wistar rats used for this study. There was minimal possibility of causing motor deficits after administering 550mg/kg of Acetaminophen. Behavioral test findings revealed slight increase in anxiety levels with low dose group with slight exploratory tendencies especially in animals in the high dose extract group. Acute exposure to *solanum Macrocarpon* leaf extracts indicated potential anxiolytic properties (Melina Giorgetti & Giuseppina Negri, 2011) [37]. The animals in the low dose group displayed less exploratory tendencies. This is possibly via decrease activity of midbrain dopaminergic neurons of nigrostriatal system (Seppa T *et al.* 2000) [36]. Acetaminophen group displayed high anxiety traits. Results show that acetaminophen alone increases brain serotonin as well as norepinephrine levels with a concomitant inhibition of liver TDO activity. (Maharaj *et al.*, 2004) [38]. Grooming and rearing activity showed no significant difference in anxiety levels as animals' response to novelty was higher in the high dose group as this in a possible indicator of stress.

There were observable histological observations attributed to the effects of *solanum macrocarpon* extracts. These effects observably increased with increases in the doses of the extract; this implies that the effects were dose dependent. Results reveal moderately condensed neurons in animals administered with 100mg/kg, 200mg/kg and 400mg/kg of *solanum macrocarpon* leaf extract. Plate 6 given 550mg/kg of ACT which did not receive any therapeutic intervention, showed neuronal degeneration and coagulative necrosis. There were also evidences of alterations of the cerebral histoarchitecture and the neuropil. Reports showed that the extract at all dosages had deleterious effects on the brain tissue and the gravity of effects increased with the dosage (Owolabi *et al.*, 2016) [40]. Plate 4 revealed that sections of cerebral cortex induced with 550mg/kg of acetaminophen and 400mg/kg *solanum macrocarpon* shows moderate healing with mild condensed neurons. This is an indication of the curative ability of *solanum macrocarpon* extracts. Olusola *et*

al., proposed that *solanum macrocarpon* extracts have protective properties in the cells of the brain using wistar rats (Olusola *et al.*, 2014) [12, 20].

Acetaminophen overdose resulted in locomotor retardation, excessive self-grooming, working-memory impairment, anxiety, derangement of liver/kidney biochemistry, antioxidant imbalance, and histological changes in the liver, kidney and cerebral cortex (Olakunle *et al.*, 2017) [39].

Conclusion

This present study proved that aqueous extract of *Solanum macrocarpon* leaf exhibited a dose dependent mild anxiolytic activity on the brain against acetaminophen induced inflammation on adult wistar rats and showed mild curative properties in the cerebral cortex. It is however recommended that further clinical and phytochemical investigations should be carried on the efficacy and safety of use this extract on various brain centers and also in astrocyte and microglial population in the limbic system as these cells perform inflammatory reactions towards drug interactions.

List of abbreviations

ACT: Acetaminophen

EPM: Elevated Plus Maze

DCA: Duration in close Arm

DOA: Duration in Open Arm

NCAE: Number of Close Arm entries

References

1. Yoon E, Babar A, Choudhary M, Kutner M, Pyrsopoulos N. Acetaminophen-Induced Hepatotoxicity: a Comprehensive Update. *Journal of Clinical and Translational Hepatology.* 2016; 4(2):131–42. doi:10.14218/jcth.2015.00052. PMC 4913076. PMID 27350943.
2. Ferri, Fred F. *Ferri's Clinical Advisor 2017 E-Book: 5 Books in 1.* Elsevier Health Sciences, 2016, 11. ISBN 9780323448383. Archived from the original on September 10, 2017. Retrieved July 6, 2017.
3. Reza MVM, Mehrdad R, Mohsen K, Rohholah D. The effect of food restriction on learning and memory of male wistar rats: A behavioral analysis, *Basic Clinical Neuroscience.* 2009; (1):20-23.
4. Sun W, Zhang L, Lu J, Yang G, Laundrie E, Salvie R. Noise exposure induced enhancement of auditory cortex response and changes in gene repression. *Neuroscience.* 2008; 156:374-80.
5. Brown RE, Corey SC, Moore AK. Differences in measures of exploration and fear in MHC-congenic C57BL/6J and B6-H-2K mice. *Behavior Genetics.* 1999; 29:263-271.
6. Oboh, Ganiyu, Ekperigin, Kazeem, Mutiu. Nutritional and haemolytic property of eggplant (*Solanum macrocarpon*) leaves, *Journal of Food Composition and Analysis.* 2005; 18(2-3):153-160. DOI: 10.1016/j.jfca.2003.12.013
7. Bukenya-Ziraba R, Bonsu KO. *Solanum macrocarpon* L. In: Grubben GJH, Denton OA (eds). *Plant Resources of Tropical Africa 2: Vegetables/Legumes*, Wageningen, Netherlands, 2004.
8. Dalziel JM. *The Useful Plants of West Tropical Africa* (New York: Longman) 1st Edn., 1937, 433–435.
9. Edijala JK, Asagba SO, Eriyamremu GE, Atomatofa U. Comparative Effect of Garden Egg Fruit, Oat and Apple

- on Serum Lipid Profile in Rats Fed a High Cholesterol Diet. *Pakistani Journal of Nutrition*. 2005; 4(4):245-249.
10. Oboh G, Ekperigin MM, Kazeem MI. Nutritional and haemolytic properties of eggplants (*Solanum macrocarpon*) leave. *Journal of Food Composition and Analysis*. 2005; 18:153-60.
 11. Oladiran JA. The effects of fruit colour, processing technique and seed treatment on the germination of *Solanum macrocarpon* L. (Igbagba). *Nigerian Journal of Technological Research*. 1989; 1(1):17-20.
 12. Olusola B Adewale, Amos Onasanya, Adewale O Fadaka, Hilda Iwere, Scholastica O Anadozie, Olukemi A Osukoya *et al.* *Oxid Antioxid Med Sci*. 2014; 3(3):225-229. ISSN: 2146-8389 <http://www.oamsjournal.com> 225 ORIGINAL ARTICLE *In vitro* antioxidant effect of aqueous extract of *Solanum macrocarpon* leaves in rat liver and brain
 13. Sodipo OA. Studies on chemical components and some pharmacological activities of *Solanum macrocarpum* Linn. fruit (Garden egg). Ph.D. Thesis, University of Maiduguri, Maiduguri, 2009.
 14. Sodipo OA, Abdulrahman FI, Sandabe UK, Akinniyi JA. Effect of *Solanum macrocarpum* Linn. on biochemical liver function in diet-induced hypercholesterolaemic rats. *Nigerian Veterinary Journal*. 2009b; 30(1):1-8.
 15. Sodipo OA, Abdulrahman FI, Sandabe UK, Akinniyi JA. Total lipids profile with aqueous fruit extract of *Solanum macrocarpum* Linn in rats. *Journal of Pharmaceutical Bioresearch*. 2009c; 6(1):10-15.
 16. Sodipo OA, Abdulrahman FI, Sandabe UK, Akinniyi JA. Effects of the aqueous fruit extract of *Solanum macrocarpum* Linn on the haematological parameters of triton-induced hyperlipidemic rats. *AJPP*. 2011a; 5(5):632-639.
 17. Sodipo OA, Abdulrahman FI, Sandabe UK, Akinniyi JA. Biochemical liver function with aqueous fruit extract of *Solanum macrocarpum* Linn. in albino rats acutely administered triton-X to induce hyperlipidaemia. *Journal of Applied Pharmaceutical Sciences*. (pages not yet determined), 2011c, 1(8).
 18. Sodipo OA, Abdulrahman FI, Sandabe UK, Akinniyi JA. Effects of the aqueous fruit extract of *Solanum macrocarpum* Linn on some haematological indices in albino rats fed with cholesterol-rich diet. *Sahel Journal of Veterinary Sciences*. 2009a; 8(2):5-12.
 19. Sodipo OA, Abdulrahman FI, Sandabe UK, Akinniyi JA. Total lipid profile and faecal cholesterol with aqueous fruit extract of *Solanum macrocarpum* in triton-induced hyperlipidaemic albino rats. *JMPR, TY-JOUR*, 2011b.
 20. Adewale, Olusola, Amos, Onasanya, Adewale, Oluwaseun *et al.* Israel: *In vitro* antioxidant effect of aqueous extract of *Solanum macrocarpon* leaves in rat liver and brain. *Oxidants and Antioxidants in Medical Science*. 2014; 3(3):225-229.
 21. Acetaminophen. The American Society of Health-System Pharmacists. Archived from the original on 5 June 2016. Retrieved 16 September, 2016.
 22. Russell FM, Shann F, Curtis N, Mulholland K. Evidence on the use of paracetamol in febrile children. *Bulletin of the World Health Organization*. 2003; 81(5):367-72. hdl:10665/268935. ISSN 0042-9686. PMC 2572451. PMID 12856055.
 23. Lewis JH, Stine JG. Review article: prescribing medications in patients with cirrhosis - a practical guide. *Alimentary Pharmacology & Therapeutics*. 2013; 37(12):1132-56. doi:10.1111/apt.12324. PMID 23638982.
 24. McKay GA, Walters MR. *Non-Opioid Analgesics. Lecture Notes Clinical Pharmacology and Therapeutics* (9th ed.). Hoboken: Wiley, 2013. ISBN 9781118344897.
 25. Mangus BC, Miller MG. *Pharmacology application in athletic training*. Philadelphia, Pennsylvania: F.A. Davis, 2005, 39. ISBN 9780803620278.
 26. Aghababian RV. *Essentials of emergency medicine*. Jones & Bartlett Publishers, 2010, 814. ISBN 978-1-4496-1846-9. Archived from the original on 17 August 2016.
 27. World Health Organization. *World Health Organization model list of essential medicines: 21st list 2019*. Geneva: World Health Organization, 2019. hdl:10665/325771. WHO/MVP/EMP/IAU/2019.06. License: CC BY-NC-SA 3.0 IGO.
 28. Prescott LF. Kinetics and metabolism of paracetamol and phenacetin. *British Journal of Clinical Pharmacology*. 10 Suppl. 1980; 2:291S-298S. doi:10.1111/j.1365-2125.1980.tb01812.x. PMC 1430174. PMID 7002186.
 29. Graham GG, Davies MJ, Day RO, Mohamudally A, Scott KF. The modern pharmacology of paracetamol: Therapeutic actions, mechanism of action, metabolism, toxicity, and recent pharmacological findings. *Inflammation pharmacology*. 2013; 21(3):201-232. doi:10.1007/s10787-013-0172-x. PMID 23719833.
 30. Marx J, Walls R, Hockberger R. *Rosen's Emergency Medicine - Concepts and Clinical Practice*. Elsevier Health Sciences, 2013. ISBN 9781455749874.
 31. Ronald FB. *Nonsteroidal anti-inflammatory drugs*. In Foye, William O., Lemke, Thomas L., Williams, David A (eds.). *Principles of Medicinal Chemistry* (Fourth ed.). Williams & Wilkins, 1995, 544-545.
 32. Brayfield, A. ed. *Paracetamol. Martindale: The Complete Drug Reference*. London, UK: Pharmaceutical Press. Retrieved 10 May, 2014.
 33. Mehta, Sweety. *Metabolism of paracetamol, (Acetaminophen), Acetanilide and Phenacetin*. *Pharma X Change info* Archived from the original on 28 October, 2012-2019.
 34. Ghanem CL, Perez, MJ, Manautou JE, Mottino AD. Acetaminophen from liver to brain; New insights into drug pharmacological action and toxicity pharmacological research. 2016; 109:119-31. doi:10.1010.1016/j.phrs.2016.02.020
 35. Fortuny J, Kogevinas M, Garcia-Closas M, Real FX, Tardon A, Garcia-Closas R *et al.* Use of Analgesics and Nonsteroidal Anti-inflammatory Drugs, Genetic Predisposition, and Bladder Cancer Risk in Spain. *Cancer Risk in Spain. Cancer Epidermology, Biomarkers and prevention*. 2006; 15(9):1696-1702. doi:10.1158/1055-9965.EPI-06-0038. PMID 16985032.
 36. Seppa T, Ruotsalainen M, Laakso I *et al.* Effect of acute nicotine administration on striatal dopamine output and metabolism in rats kept at different ambient temperatures. *Brit J Pharmacol*. 2000; 130:1147-1155.
 37. Melina Giorgetti, Giuseppina Negri. Plants from Solanaceae family with possible anxiolytic effect reported on 19th century's Brazilian medical journal. *Rev. bras. Farmacogn*, 2011, 21(4). <https://doi.org/10.1590/S0102-695X2011005000106>
 38. Maharaj H, Maharaj DS, Saravanan KS, Mohanakumar KP, Daya S. Aspirin curtails the acetaminophen-induced

- rise in brain norepinephrine levels. *Metabolic Brain Disorders*. 2004; 19(1-2):71-7.
39. Olakunle Onaolapo, Adekola Moses, Azeez Taiwo, Salami Adejoke, Onaolapo Y. Methionine and silymarin: A comparison of prophylactic protective capabilities in acetaminophen-induced injuries of the liver, kidney and cerebral cortex. *Biomedicine and Pharmacotherapy*. 2017; 85:323-33
40. Owolabi JO, Olatunji SY, Olanrewaju AJ. Solanum macrocarpon Leaf Extract Effects on Cerebral Cortex Microanatomy in Isoproterenol Induced Myocardial Infarction. *Journal of complementary and Alternative Medical Research*. 2016; 1(1):1-8. doi <https://doi.org/10.9734/JOCAMR/2016/26867>
41. Olusola B Adewale, Amos Onasanya, Adewale O Fadaka, Hilda Iwere, Scholastica O Anadozie, Olukemi A Osukoya *et al.* *In vitro* antioxidant effect of aqueous extract of Solanum macrocarpon leaves in rat liver and brain. *Oxid Antioxid Med Science*. 2014; 3(3):225-229. doi: 10.5455/oams.191214.or.079.