Journal of Pharmacognosy and Phytochemistry

Available online at www.phytojournal.com

E-ISSN: 2278-4136
P-ISSN: 2349-8234
www.phytojournal.com
JPP 2020; 9(6): 41-44
Received: 28-08-2020
Accepted: 12-10-2020

Konan Kouakou Séverin
Biotechnology and Valorisation of Agroressources Laboratory, Peleforo GON Coulibaly University, Korhogo, BP 1328 Korhogo, Côte d'Ivoire

Tiekpa Wawa Justine
Biotechnology and Valorisation of Agroressources Laboratory, Peleforo GON COULIBALY University, Korhogo, BP 1328 Korhogo, Côte d'Ivoire

Moroh Aboya
Biotechnology and Valorisation of Agroressources Laboratory, Peleforo GON COULIBALY University, Korhogo, BP 1328 Korhogo, Côte d'Ivoire

Corresponding Author:
Konan Kouakou Séverin
Biotechnology and Valorisation of Agroressources Laboratory, Peleforo GON Coulibaly University, Korhogo, BP 1328 Korhogo, Côte d'Ivoire

Anticoccidial activity of the aqueous extract of *Anogeissus leiocarpus* leaves in broiler chickens

Konan Kouakou Séverin, Tiekpa Wawa Justine and Moroh Aboya Jean-Luc

Abstract
The aim of this study was to evaluate the anticoccidial activity of the aqueous extract of the leaves of *Anogeissus leiocarpus*. To do this, 100 broilers were divided into 4 batches of 25 chickens. At 8th day of age, the chickens of groups B, C and D were infected orally with 10.000 sporulated oocysts of *Eimeria tenella*. Then, chickens of groups C and D were treated respectively with 10g/L of *A. leiocarpus* and 0.2g/L of Vetacox S®. The results showed that the aqueous extract of *A. leiocarpus* significantly improved ($p< 0.05$) weight growth, weight gain of group C compared to group B. In addition, the aqueous extract of *A. leiocarpus* significantly reduced ($p< 0.05$) oocyst number and lesion score of group C compared to group B. In conclusion, the aqueous extract of *A. leiocarpus* could be used in the prevention and treatment of coccidiosis caused by *E. tenella*.

Keywords: *Anogeissus leiocarpus*, *Eimeria tenella*, coccidiosis, broiler chickens

Introduction
Coccidiosis is a parasitic disease caused by protozoa of genus Eimeria characterized by hemorrhagic enteritis. The disease causes real economic losses by causing poor growth and feed efficiency in broilers even leading to high mortality in poultry industry [1]. Control of coccidiosis in modern intensive poultry production is based on the use of synthetic anticoccidial drugs in feed of poultry [2], but the problem of drug resistance, food safety and public health concerns about drug residues in poultry products direct research towards alternative solutions based on the use of plant extracts [3, 4]. Indeed, several studies have already demonstrated the positive effect of plant extract in the prevention and treatment of avian coccidiosis [5]. Thus, the objective of the present study is to evaluate the anticoccidial activity of the aqueous extract of *A. leiocarpus* leaves, a plant used in the prevention and treatment of various parasitic diseases [6,7].

Material and Methods
Aqueous extract preparation
The aqueous extract used for the study was obtained from *A. leiocarpus* leaves collected at Peleforo Gon Coulibaly University. The harvested leaves were dried and then pulverized. 20g of *A. leiocarpus* powder were added to 2L of distilled water. The mixture is stirred for 48 h, filtered through Wathman paper and evaporated under vacuum at 30°C [8]. The dried powder obtained constitutes the aqueous extract

Birds treatment
For the study, 100 one-day-old Hubbard chicks were purchased from a local hatchery. Chicks were reared on Floor Pens Under standard management practices. The experimental chicks were provided feed and water *ad libitum*. All birds were vaccinated against Newcastle disease, Gumboro, and infectious bronchitis. After 7 days of acclimatization, the chickens were divided into 4 groups (A, B, C and D) of 25 chicks per group.
Group A: uncontaminated and untreated.
Group B: contaminated and untreated.
Group C: contaminated and treated with 10g/L of aqueous extract of *A. leiocarpus*
Group D: contaminated and treated with 0.2g/L of Vetacox S®

The oocysts used to infected chickens were obtained from caeca of naturally infected chickens. The identification of species was made on the basis of morphological criteria [9]. At 8th day of age, chickens of groups C and D received orally 10.000 sporulated oocysts of *E. tenella*. Seven days after inoculation, chickens in groups C and D received 10g/L of aqueous extract of *A. leiocarpus* and 0.2g/L of Vetacox S® respectively for one week.

Evaluation of anticoccidial effects

To evaluate the anticoccidial activity of the aqueous extract of *A. leiocarpus*, all chicks from each group were weighed on day of inoculation (8th day of age) and then reweighed the consumption index (CI) was determined at the 15th, 22th, 29th, 36th and 45th day of age. The weight of treated chicks was compared with control groups. Fecal samples of 5 chicks for each group were investigated for oocyst excretion at the same date. The counting of oocysts was done by McMaster technique. Three chicks from each group were sacrificed for post-mortem examination at day 8th, 15th, 29th, 45th day of age. Caecal lesion were scored by the lesion scoring technique described [10].

Statistical analysis

The data obtained were analyzed with Graphpad software. 5.1. Data are expressed as mean ± SEM. Statistical analysis of the results was done from the ANOVA test to determine if there is a significant difference between the means. The significance level was set at $p< 0.05$.

Results

The weight growth, weight gain and consumption index were presented in Table 1. The results obtained show that the weight growth and weight gain of the contaminated chickens (groups B, C and D) were significantly lower ($p< 0.05$) compared to group A one week post infection (PI). The consumption index of those groups increased at the same period compared to group A. At 22nd day of age, one week after the start of treatment, the results showed that weight growth and weight gain of treated chickens were significantly higher compared to contaminated and untreated chickens (group B). However, this weight growth was significantly lower ($p< 0.05$) compared to uncontaminated and untreated chickens (group A). At the end of the study (45th day of age), the results showed that the weight of chickens contaminated and treated with Vetacox S® (1391±20g) were significantly higher ($p< 0.05$) compared to the weight of chickens contaminated and treated with *A. leiocarpus* (1336±70). However, no significant difference ($p< 0.05$) was observed between the weight gain of chickens treated with the aqueous extract of *A. leiocarpus* and those treated with the anticoccidial Vetacox S®.

Table 1: Evolution of Body Wight (BW), Body Wight gain (BWG) and Consumption index (CI)

Groups		Days					
		8	15	22	29	36	45
BW (g)	A	153.6±6^{a}	281±14^{a}	501±19^{a}	754±11^{a}	1035±3^{a}	1341±4^{a}
	B	151.2±13^{a}	230±9^{b}	340±15^{b}	471±22^{b}	672±2^{b}	897±2^{b}
	C	150.4±10^{a}	227±20^{b}	450.4±25^{c}	708±35^{c}	1000±3^{a}	1336±7^{a}
	D	150.5±8^{a}	233.2±12^{b}	471±12^{d}	738±22^{a}	1038±4^{a}	1391±2^{c}
BWG (g)	A	0^{a}	127.4±11^{a}	220.6±9^{a}	252±8^{a}	281±35^{a}	306±18^{a}
	B	0^{a}	78±14^{b}	110±11^{b}	130±14^{b}	195±14^{b}	225±16^{b}
	C	0^{a}	76±8^{b}	202±13^{c}	277±10^{c}	291±12^{a}	336±2^{ac}
	D	0^{a}	80±10^{b}	236±10^{d}	284±15^{c}	300±22^{a}	352±32^{c}
CI	A	0	1.50	2.2	2.54	2.78	2.80
	B	0	2.01	3.1	3.6	3.8	4
	C	0	1.98	2.35	2.7	2.8	2.95
	D	0	2	2.2	2.40	2.6	2.75

Means within a column with different superscript letters denote significant differences ($P< 0.05$)

Tables 2 show the lesion score during the study. These results showed that before infection, no lesion score were recorded in chickens from different groups. One week after infection (D15), the chickens from the three infected groups recorded high lesion score. At the same date, those groups recorded a high parasite number in the faeces of chickens (Table 3). Statistical analysis of the number of oocyst indicates that there is no significant difference ($p< 0.05$) between the various parasite number. At 29th day of age, one week after the end of the treatment, lesion score chickens of group C was significantly lower ($p< 0.05$) compared to chickens from group B. At the end of the study, lesions observed in the chickens treated with the aqueous extract of *A. leiocarpus* were not significantly different ($p< 0.05$) compared to chickens treated with the anticoccidial Vetacox S®. Furthermore, lesions observed in the chickens from group C were significantly lower ($p< 0.05$) compared to group B. Number of oocyt the chickens of group B was significantly higher ($p< 0.05$) compared to groups C and D. No significant difference ($p< 0.05$) was observed between the oocyst number of group C and D.

Table 2: Evolution of lésion score (LS)

Groups		Days			
		8	15	29	45
LS	A	0^{a}	0^{a}	0^{a}	0^{a}
	B	0^{a}	3.3±0.5^{b}	3.6±0.5^{b}	2.6±1^{b}
	C	0^{a}	3.6±0.5^{b}	1.6±1^{c}	0.3±0.5^{a}
	D	0^{a}	3.3±0.5^{b}	0.6±0.5^{a}	0.3±0.5^{a}

Means with in a column with different super script letters denote significant differences ($P< 0.05$)

Table 3: Evolution of oocyst excretion (OPG x1000)

Groups		Days					
		8	15	22	29	36	45
OPG (x 1000)	A	0^{a}	0^{a}	0^{a}	0^{a}	0^{a}	0^{a}
	B	0^{a}	45.6±9b	61.6±6^{b}	53.6±6^{b}	48.2±8^{b}	35±4^{b}
	C	0^{a}	45.4±7^{b}	28.6±5^{c}	19±2.9^{c}	1±0.3^{c}	0.2±0.1^{c}
	D	0^{a}	46.8±10^{b}	25±3.3^{c}	11±2.3^{d}	0.7±0.2^{c}	0.1±0^{c}

Means with in a column with different super script letters de note significant differences ($P< 0.05$)

Figure 1 show the mortality rate recorded during the study. The results indicate that the contaminated and untreated chickens (group) recorded a mortality rate of 20% against 3% for group A, 8% and 5% respectively for groups C and D.

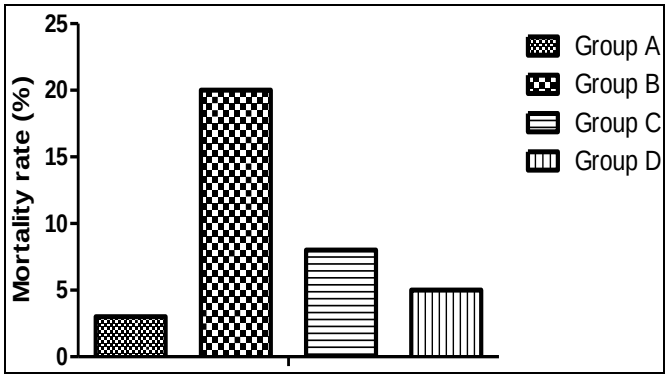

Fig. 1: Mortality rate

Discussion

Treatment of the chickens with the aqueous extract of *A. leiocarpus* and the anticoccidial Vetacox S® improved weight growth and weight gain while reducing the consumption index. These results were agreed with the results of other studies which have reported that the treatment of broilers chickens infected by *E. tenella* with *Allium sativum* and *Punica granatum* improve weight growth and weight gain [11]. In addition, studies of other authors have also shown in their studies an improvement of weight growth in broilers infected with a mixture of Eimeria species and treated with a *Calotropis procera* [12]. In addition, work on the anticoccidial activity of a mixture of plant extracts [13] has reported that this mixture increases the weight gain of treated chickens. The treatment of the chickens with the aqueous extract of *A. leiocarpus* reduced the lesion score and the oocyst number. Our results were agreed with those founds in a study of treating broilers infected with *E. spp*. with olive pulp which showed that olive pulp reduced oocyst excretion [14].

Other authors have also reported that the extract of "Shi yung Zi" reduces the death rate while improving body weight growth in broilers infected with *E. tenella* [15]. These results could be explained by the presence of phenolic compounds in the extract of *A. leiocarpus* [16]. In fact, phenolic compounds with antioxidant properties were beneficial in the control of coccidiosis [17]. Parasites during their development alter intestinal cells and affect nutrient absorption, which decrease weight growth and increase consumption index [18]. The results could also be explained by the antibacterial properties of *A. leiocarpus* [19, 20].

Indeed, several authors suggested that, plants contain variety of phytochemical compounds such as polyphenols, alkaloids have antimicrobial and anticoccidial properties have the ability to interfere with the cell membrane or cytoplasm of parasite and resulting death of parasite [21]. In addition, other studies have reported that phenolic compounds such as tannins bioactive ingredients of plants have ability to improve and regenerate the physiological structure of the intestinal epithelium and ultimately support the digestive capacity through increased absorption of nutrients and assimilation [22].

Conclusion

The results of the present study revealed that the aqueous extract of *A. leiocarpus* showed anticoccidial activity against *E. tenella*. Treatment of chickens with aqueous extract of *A. leiocarpus* improved body weight reducing lesion score. In view of these results, the aqueous extract of *A leiocarpus* could be used as an alternative solution for the control and treatment of coccidiosis.

References

1. Lee JT, Broussard C, Fitz-Coy S, Burke P, Eckert NH, Stevens SM *et al.* Evaluation of live oocyst vaccination or salinomycin for control of field-strain Eimeria challenge in broilers on two different feeding programs. Journal of Applied Poultry Research 2009;18:458–464.
2. Allen PC, Fetterer RH. Recent advances in biology and immune biology of Eimeria species and in diagnosis and control of infection with these coccidian parasites of poultry. Clinical Microbiology Reviews 2002;15:58-65.
3. Abbas R, Iqbal Z, Khan A, Sindhu Z, Khan J, Khan M *et al.* Options for integrated strategies for the control of avian coccidiosis. International Journal of Agriculture and Biology 2012;14:1014-1020
4. Kostadinović L, Popović S, Pelić DL, Čabarkapa I, Đuragić O, Lević J. Medicinal plants as natural alternative to coccidial synthetic drugs in broiler chicken production. Journal of Agronomy, Technology and Engineering Management 2019;2(5):325-334.
5. Wiedosari E, Wardhana AH. Anticoccidial Activity of Artemisinin and Extract of *Artemesia annua* Leaves in Chicken Infected by *Eimeria tenella*. Jurnal Ilmu ternak dan Veteriner 2017;22(4):196-204.
6. Mukhtar Y, Abdu K, Maigari AK. Efficacy of *Anogeissus leiocarpus* (DC.) as Potential Therapeutic Agent against Trypanosomiasis Diseases: A Review. International Journal of Health and Pharmaceutical Research 2017;3(3):2045-4673.
7. Kone KHC, Coulibaly K, Konan KS. Identification of some plants used in ethnoveterinary medicine in Sinématiali (North of Côte d'Ivoire). Journal of Applied Biosciences 2019;135:13766-13774.
8. Touré A, Bahi C, Ouattara K, Djaman AJ, Coulibaly A. Phytochemical screening and *in vitro* antifungal activities of extracts of leaves of *Morinda morindoides* (Morinda, Rubiaceae). Journal of Medecinal Plants Research 2011;5(31):6780-6786.
9. Davis LR, Hammond DM, Long PL. The Coccidia. University Park Press: Baltimore 1973, 411-458.
10. Johnson J, Reid WM. Anticoccidial drugs: lesion scoring techniques in battery and floor pen experiments with chickens. Experimental Parasitology 1970;28:30-36.
11. Al-Shaibani IRM, Al-Khadher AMA, AlHibah AZH. Anticoccidial Activity of *Allium sativum* and *Punica granatum* against Experimentally Induced Eimeria tenella Infection in Broiler Chickens. Asian Journal of Research in Animal and Veterinary Sciences 2020;5(4):20-29.
12. Chauhan S, Singh VS, Thakur V. Effect of Calotropis procera (madar) and amprolium supplementation on parasitological parameters of broilers during mixed Eimeria species infection. Veterinary World 2017;10(8):864-868.
13. Pop LM, Varga E, Coroian M, Nedișan ME, Mircean V, Dumitrache MO *et al.* Efcacy of a commercial herbal formula in chicken experimental coccidiosis. Parasites Vectors 2019;12:343-352.
14. Debbou-Iouknane N, Nerín C, Amrane M, Ghemghar M, Madani K. In Vitro Anticoccidial Activity of Olive Pulp (*Olea europaea* L. var. Chemlal) Extract Against Eimeria Oocysts in Broiler Chickens. Acta Parasitologica 2019;64:887-897.

15. Song X, Li Y, Chen S, Jia R, Huang Y, Zou Y *et al.* Anticoccidial Effect of Herbal Powder "Shi Ying Zi" in Chickens Infected with *Eimeria tenella*. Animals 2020;10:1484-1499.
16. Orlando G, Ferrante C, Zengin G, Sinan KI, Bene K, Diuzheva A *et al.* Qualitative Chemical Characterization and Multidirectional Biological Investigation of Leaves and Bark Extracts of *Anogeissus leiocarpus* (DC.) Guill. & Perr. (Combretaceae). Antioxydants 2019;8(9):343-371.
17. Masood S, Abbas RZ, Iqbal Z, Mansoor MK, Sindhu ZD, Zia MA *et al.* Role of Natural Antioxidants for the Control of Coccidiosis in Poultry. Pakistan Veterinary Journal 2013;33(4):401-407.
18. Udo EJ, Abba AM, Abdulhamid Y, Mudassir I. In-vivo evaluation of anticoccidial efficacy of aqueous extract of *Allium sativum* and *Carica papaya* in Experimentally Infected Broiler Chicks. Current Trends in Biomedical Engineering & Biosciences 2018;16(5):001-007.
19. Ali EO, Tor-Anyiin TA, Igoli JO, Anyam JV, Hammuel C. Antimicrobial activity of *Anogeissus leiocarpus* stems bark extracts and an isolate from the plant against some microbes. American Journal of Research Communication 2017;5(8):9-25.
20. Lawal TO, Bamiduro TB, Ofonmbuk JM, Elufioye TO, Adeniyi BA, Mahady GB. Antibacterial effects of *Anogeissus leiocarpus* (DC.) Guill. & Perr. and *Terminalia glaucescens* Planch. Ex Benth. on rapidly growing mycobacteria species. African Journal of Microbiology Research 2017;11(12):495-503.
21. Muthamilselvan T, Kuo T, Wu Y, Yang W. Herbal remedies for coccidiosis control: A review of plants, compounds, and anticoccidial actions. Evidence-based Complementary and Alternative Medicine 2016;1:1-19.
22. Adibmoradi M, Navidshad B, Seifdavati J, Royan M. Effect of dietary garlic meal on histological structure of small intestine in broiler chickens. The Journal of Poultry Science 2006;43:378-383.